Provided by:

KELO-COTE®
SCAR PREVENTION
& TREATMENT

Training Manual

Module 1

Images purchased from Shutterstock unless otherwise stated

Job bag no. JB-000366
Date of preparation: Feb 2021

Provided by:

KELO-COTE®
SCAR PREVENTION
& TREATMENT

An Overview of Wound Healing and Pathological Scarring

OBJECTIVES

At the end of this session, you should be able to:

- Describe the structure and function of healthy skin
- Explain the process of wound healing
- Describe the processes involved in pathological scarring
- Differentiate between hypertrophic and keloid excessive scarring
- Discuss the personal burden of excessive scarring

Provided by:

KELO-COTE®
SCAR PREVENTION
& TREATMENT

The Structure and Function of Healthy Skin

SKIN FUNCTION

The skin accounts for 15% of total bodyweight in adults[1]

Protects against:

Physical trauma[1]



Chemicals[2]



Microbial invasion[2]



Regulates:

Body temperature[1,2]

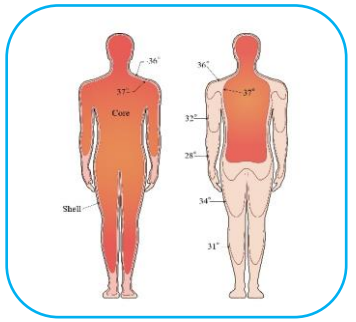

Water & electrolyte balance[2]

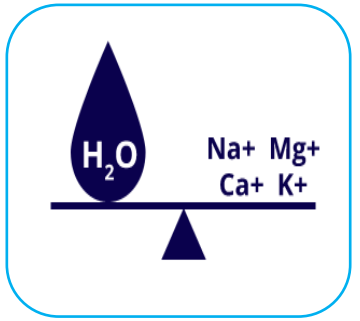

Plays key roles in:

Sensation[1]



Vitamin D synthesis[2]



SKIN STRUCTURE: LAYERS

- 3 primary layers – epidermis, dermis and hypodermis (typically called the subcutis or subcutaneous fat)[2]
- The thickness of each layer depends on its location in the body[1]
- Thinnest epidermis is on the eyelid, while thickest is on the palms of the hands and the soles of the feet[1]

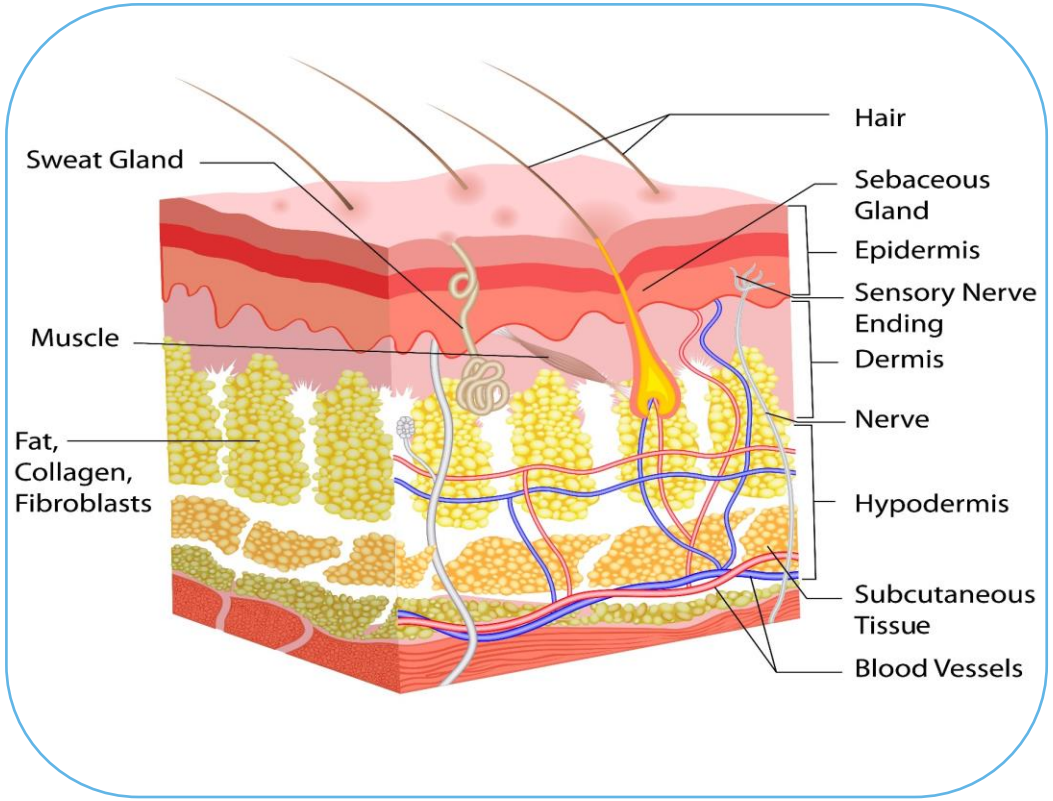

THE EPIDERMIS: STRUCTURE

- The outermost layer of the skin[1]
- Composed of several strata:[1]
  - Stratum corneum
  - Stratum granulosum
  - Stratum spinosum
  - Stratum basale
  - Basale/germinativum
- The stratum corneum is relatively waterproof and when intact protects the body from external insults and microbial invasion[2]

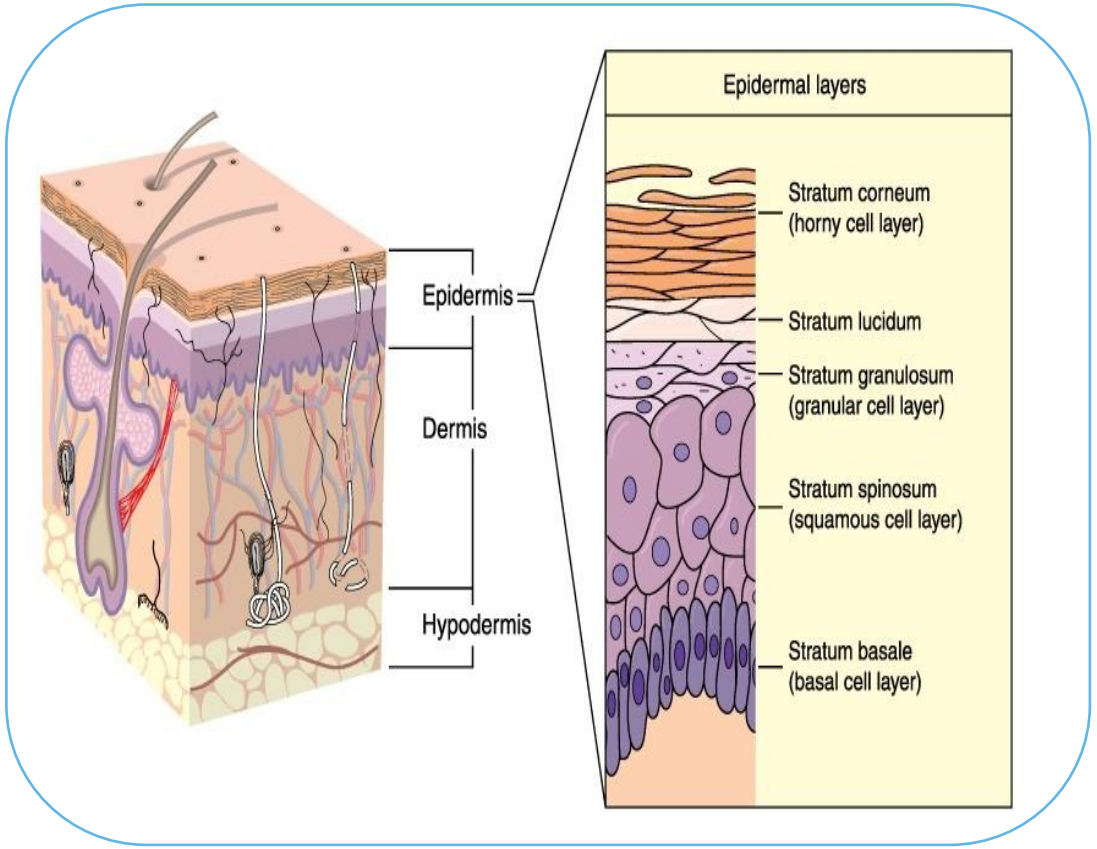

THE EPIDERMIS: CELL TYPES

- 80-95% of cells within the epidermis are keratinocytes[1-3]
  - These originate in the stratum basale and move up through the layers of the epidermis as they mature into corneocytes
  - When they reach the outer epidermis the corneocytes are shed and replaced in a constant cycle of renewal
- Merkel cells are attached to keratinocytes within the stratum basale[1,2]
  - They are responsible for sensitivity to pressure and touch – most densely packed in areas such as the fingertip epidermis
- Melanocytes in the stratum basale produce melanin which colours the skin and protects from ultraviolet radiation[1,3]
  - Melanocytes transfer melanin to keratinocytes so that it is transported upwards to the outer layer of the skin
- Langerhans cells (a type of dendritic cell) play a key role in the immune function of the skin[1,2]

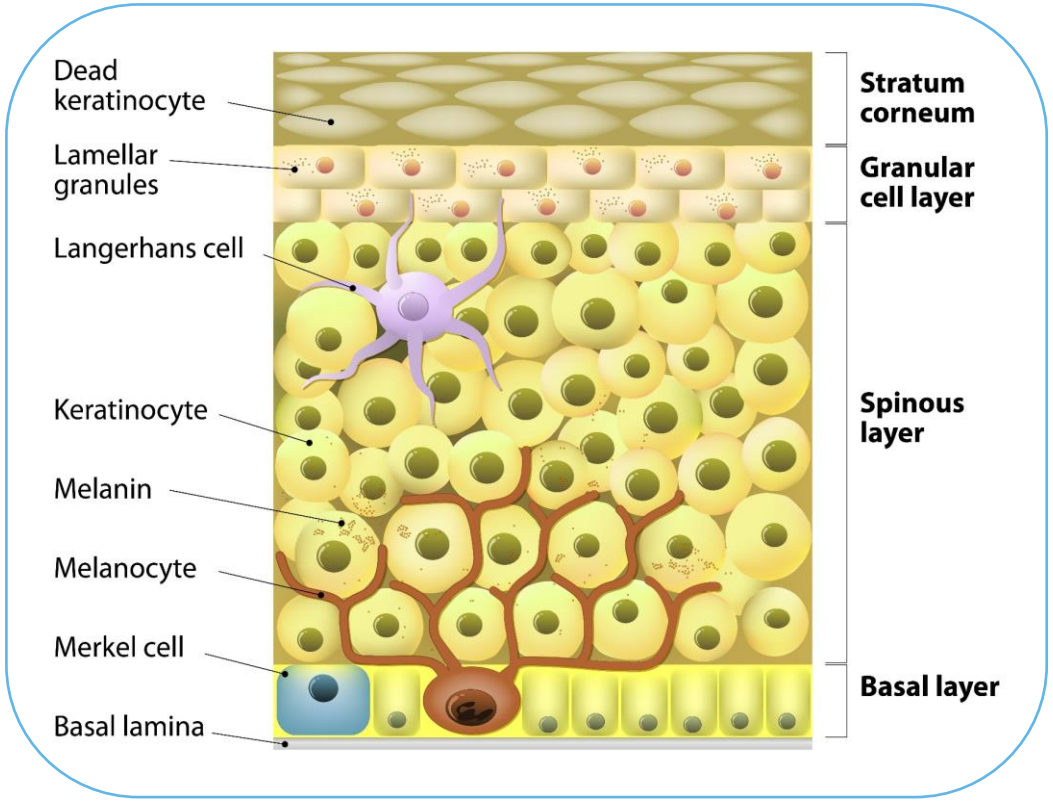

THE DERMIS: STRUCTURE AND FUNCTION

- The middle layer of the skin[1,2]
- Thicker than the epidermis[1]
- Responsible for the pliability, elasticity and tensile strength of the skin[1]
- Contains structures such as the hair follicles, sebaceous glands, sweat glands[1,2]
- Protects the body from mechanical injury[1]
- Binds water[1]
- Plays a key role in thermoregulation[1]

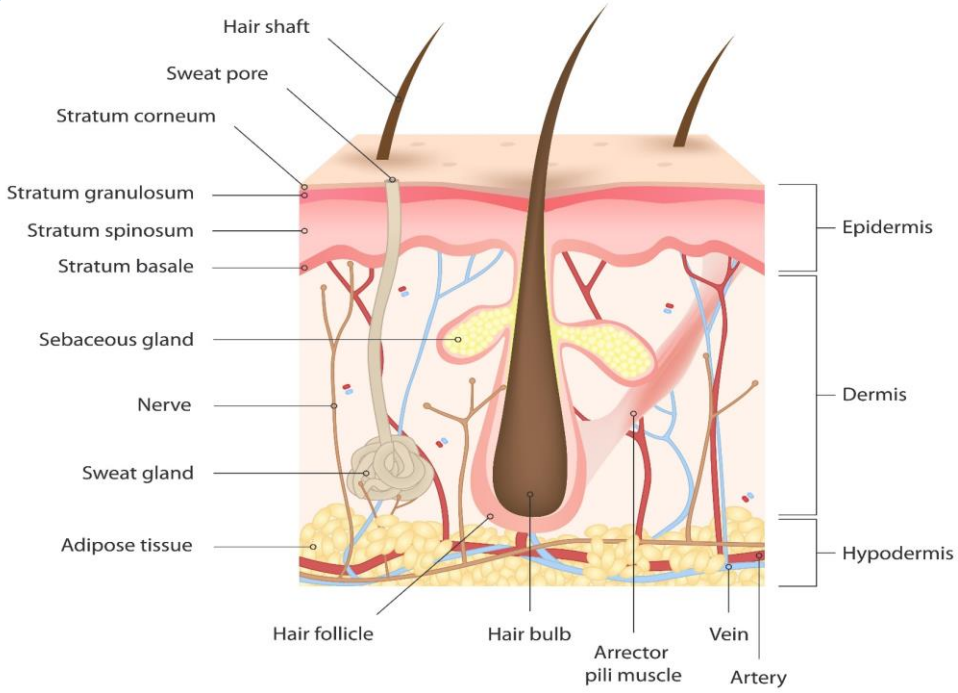

THE DERMIS: CELL AND TISSUE TYPES

- Principal component is collagen – collagen fibrils are the major source of stress resistance in the skin[1]
- Elastic fibres maintain the elasticity of the skin but have little capacity to resist skin deformation and tearing[1]
- Contains sensory receptors[1]
- Nerve cells and small blood vessels (arterioles and venules) are found together as neurovascular bundles[1]
- Mast cells present in the dermis play a role in mediating the immune response and regulating inflammation[1]
    - They may also be involved in the allergic response

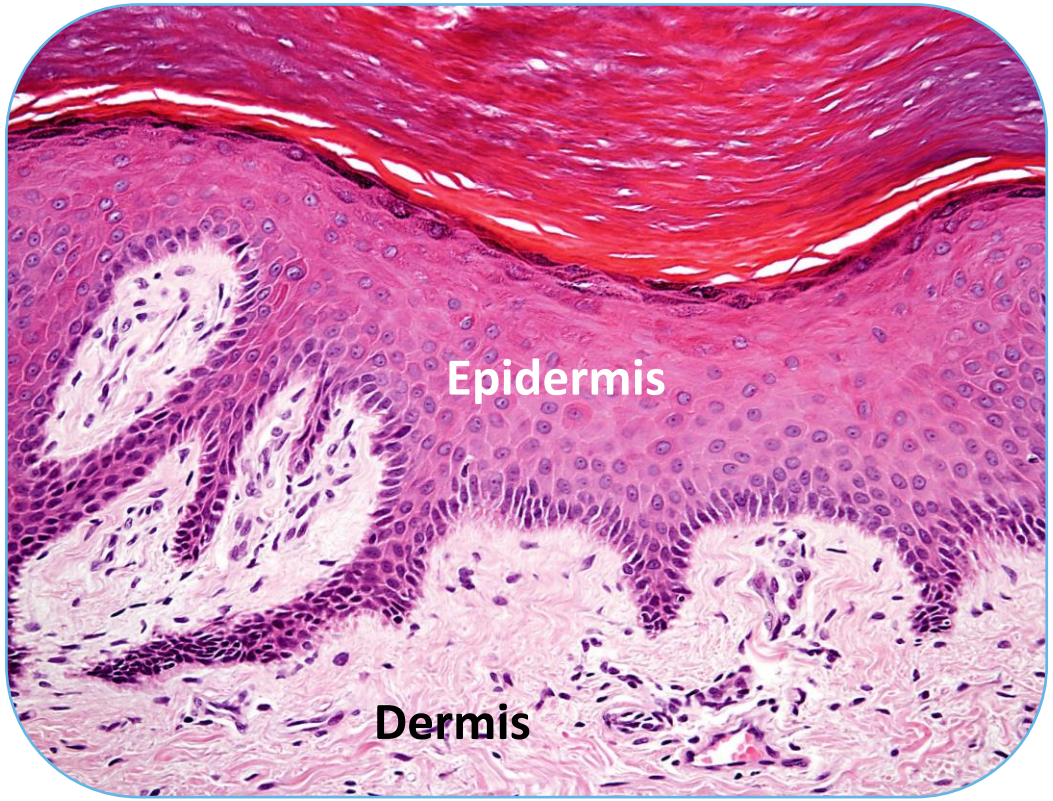

THE HYPODERMIS (SUBCUTIS)

- Lies beneath the dermis and is primarily composed of fat cells interspersed with fibrous tissue[2]
- The thickness of the subcutis depends on the body area[1]
- The subcutis serves three purposes:[4]
  - Insulation from heat and cold
  - Provision of protective padding
  - Energy storage

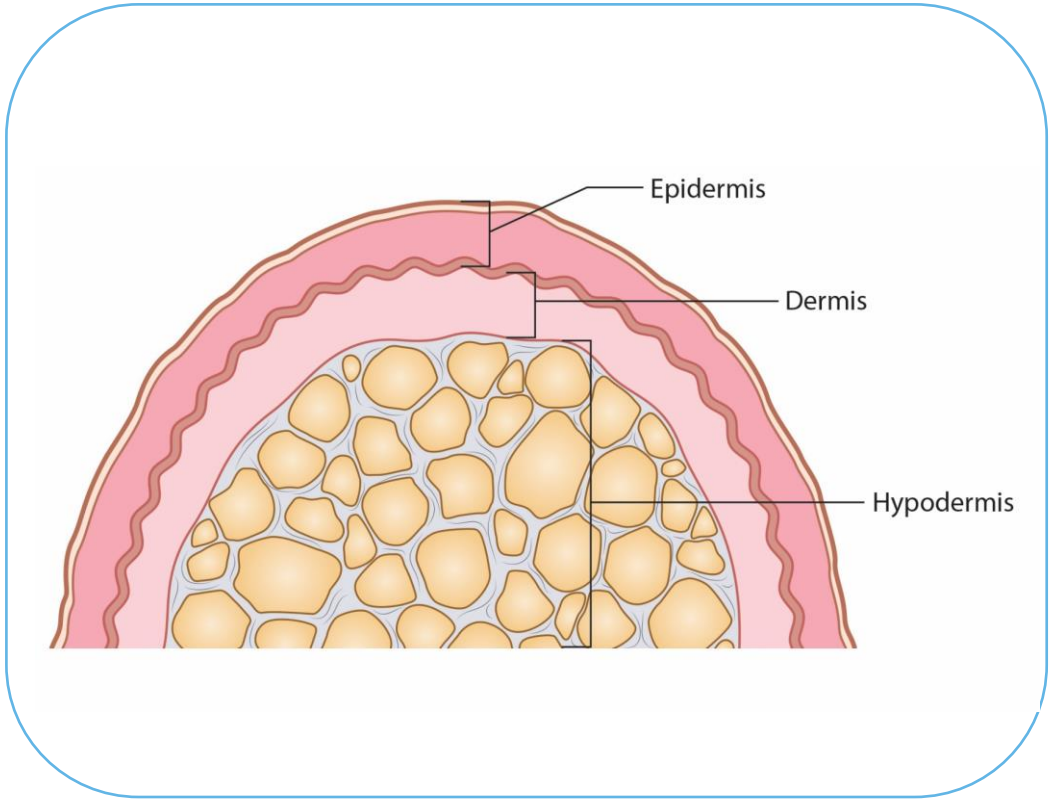

Adapted from http://www.dartmouth.edu/~anatomy/Histo/lab_4/skin/DMS033/popup.html

Provided by:

KELO-COTE®
SCAR PREVENTION
& TREATMENT

Wound Healing

THE WOUND HEALING PROCESS: TIMELINE

- Uncomplicated wound healing restores the integrity of the skin and protects from infection and dehydration[5]
- There are four phases of wound healing, which overlap:[5,6]
  - Cessation of blood loss and clot formation (haemostasis)
  - Inflammatory phase
  - Proliferative phase
  - Remodelling phase
- After the four phases above, scar maturation occurs[5,6]

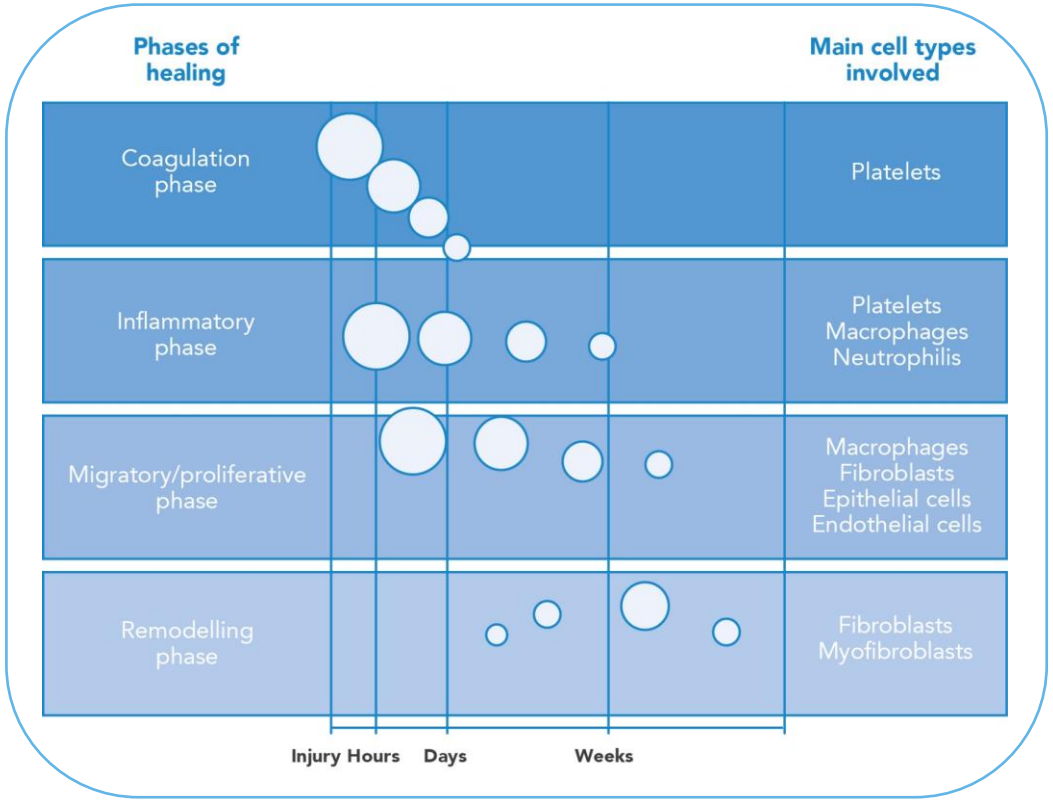

Adapted from http://accessmedicine.mhmedical.com/content.aspx?bookid=392&sectionid=41138988

WOUND HEALING: HAEMOSTASIS

- Following acute tissue injury, vasoconstriction occurs to limit blood loss[5]
- Large numbers of platelets migrate to the site of the wound[5]
- They adhere to the blood vessel wall and aggregate to form the initial haemostatic plug[5]
- Mediators are released from platelets that initiate blood clot formation, and this is known as the coagulation cascade[5]
- These also stimulate keratinocytes at the wound edge to proliferate and migrate to cover the wound[5]

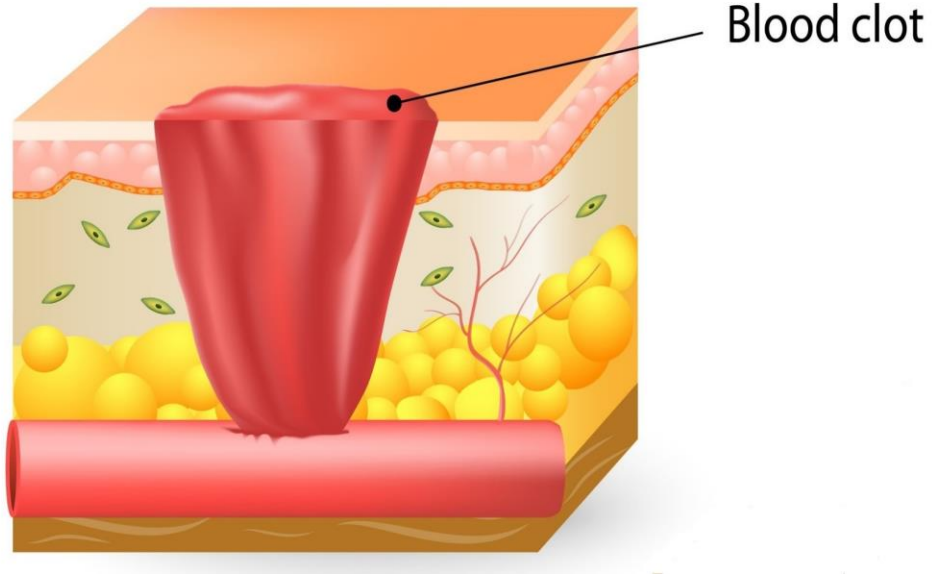

WOUND HEALING: INFLAMMATION

The blood clot and surrounding tissues release chemical mediators that attract specific cells within the blood to the wound site[7,8]

- Neutrophils are the first to arrive at the site of injury[7,8]
  - Clear cellular debris and invading microbes
- Macrophages[7,8]
  - Promote inflammation by recruiting and activating other white blood cells
  - Induce cell death and clear dead cells, including neutrophils
- Lymphocytes (B-cell and T-cells)[5]
  - These arrive during the latter stages of the inflammatory phase and raise the immune response against microbes and other foreign material in the wound

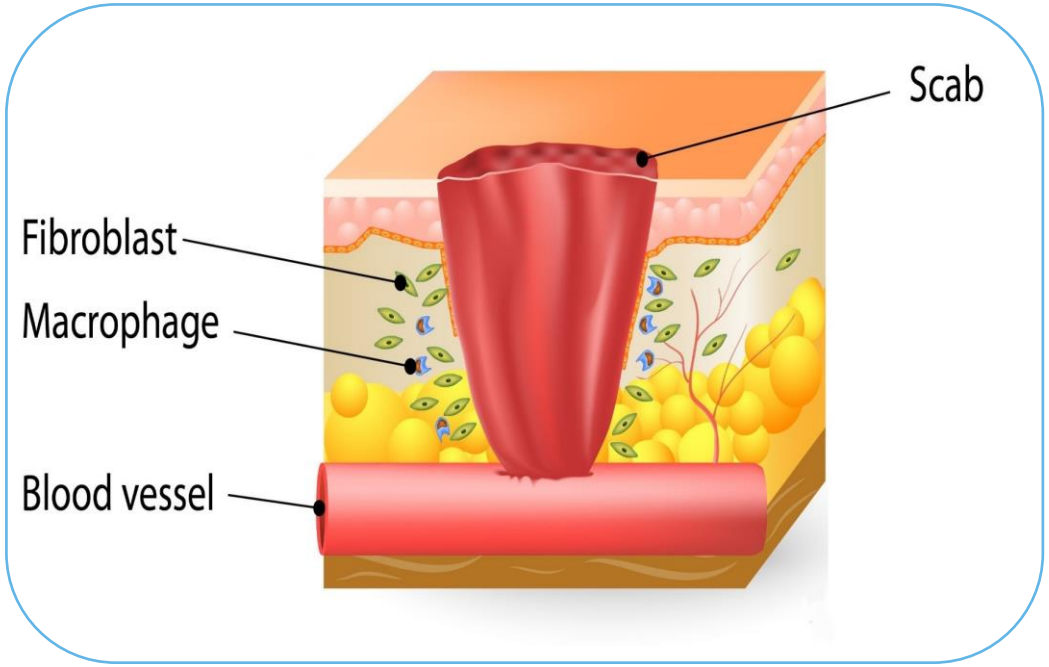

WOUND HEALING: PROLIFERATION

- Starts at about day 3 and lasts for 2-4 weeks after the wound has occurred[7]
- The fibrin-platelet matrix is degraded[5]
- Fibroblasts, endothelial cells and keratinocytes migrate to the wound area[5,7]
- Fibroblasts proliferate and produce collagen and other connective tissues[7]
- These substances help to construct the new extracellular matrix (ECM) within the wound, which becomes organised around epithelial, endothelial and smooth muscle cells[7]
- Keratinocytes migrate to beneath the ECM[5]
- By 3-5 days soft pink granular tissue is visible beneath the scab over the wound[7]
- New blood vessels populate this tissue[5,7]

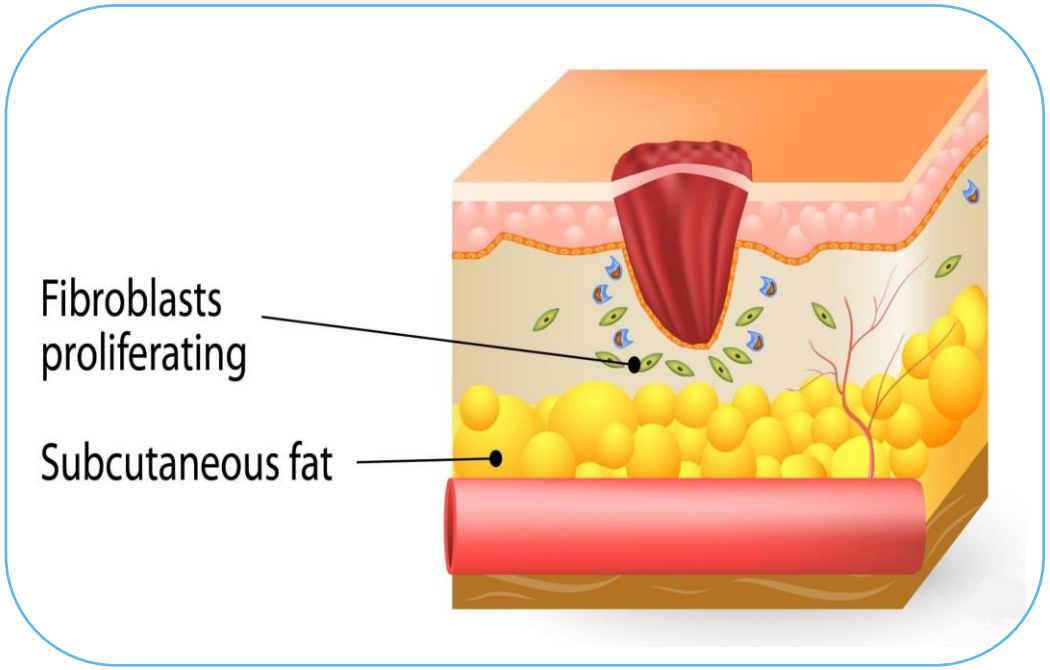

WOUND HEALING: REMODELLING

- The synthesis and remodelling of the ECM occurs at the same time as the development of the granulation tissue[7]
- There is a continuous cycle of collagen breakdown and synthesis as the ECM is constantly remodelled[7]
- This phase reaches a steady state at ~21 days after the wound has occurred[7]
- Wound contraction occurs via interactions between fibroblasts/myofibroblasts and the surrounding ECM[7]

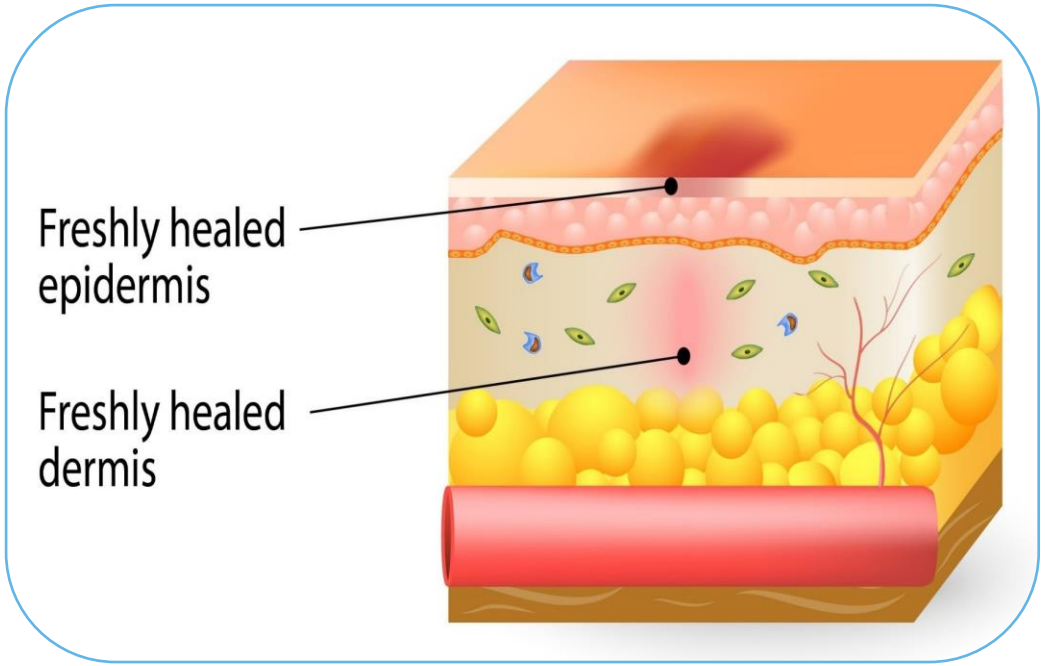

WOUND HEALING: SCAR MATURATION

- Scars are the end point of normal tissue repair following injury[6]
- As the scar matures, collagen bundles increase in diameter[7]
- This increases the tensile strength of the wound[7]
- However, the scar tissue achieves a maximum of only ~80% of the strength of unwounded skin[7]
- Scar tissue does not have the texture of healthy skin[9]



Image purchased from iStock

SYSTEMIC FACTORS AFFECTING WOUND HEALING

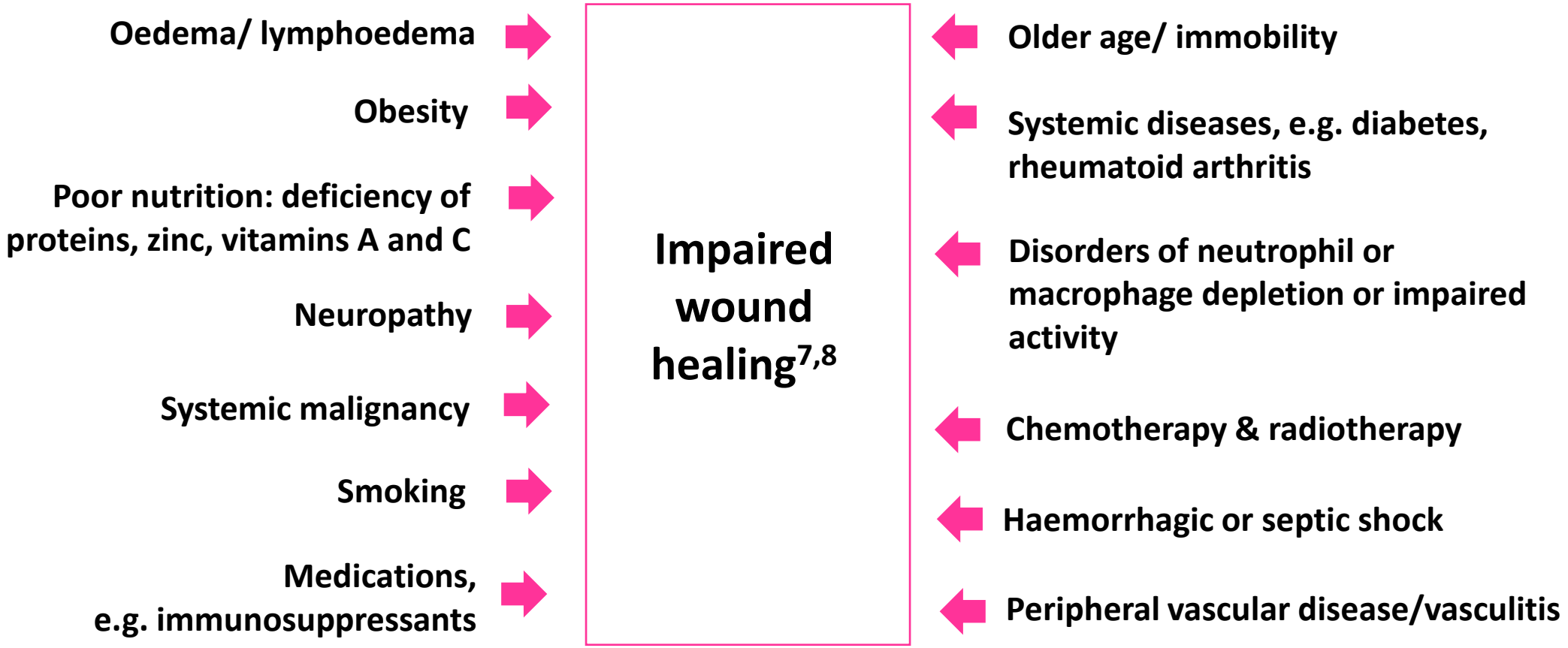

Provided by:

KELO-COTE®
SCAR PREVENTION
& TREATMENT

Pathological Scarring

COMMON CAUSES OF SCARRING[10]

Trauma & emergency surgery



Infections



Burns



Elective surgery



FAMILY OF PATHOLOGICAL SCARS[6]

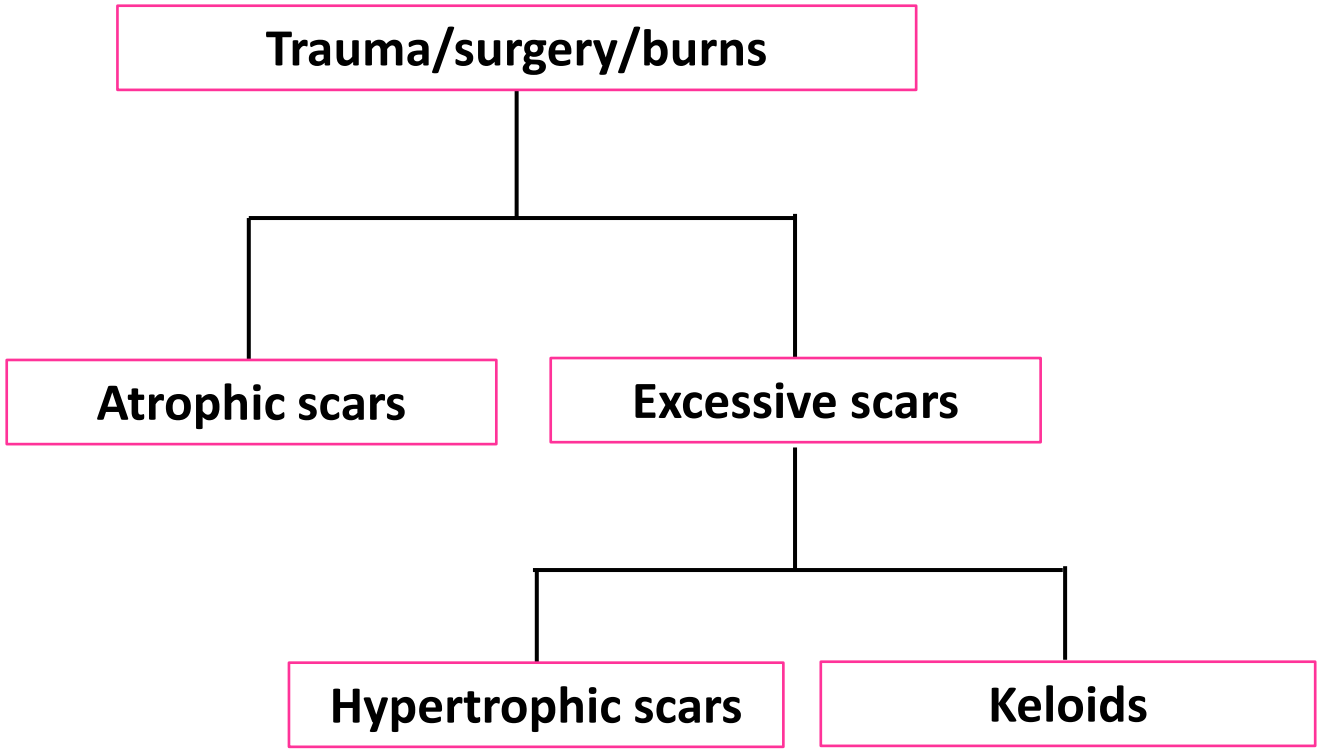

Please note: KELO-COTE is not indicated to treat atrophic scars

ATROPHIC SCARS

- Hollow, pitted appearance[6]
- Most common causes include:[11]
  - Acne
  - Cysts
  - Chickenpox



Please note: KELO-COTE is not indicated to treat atrophic scars

PATHOPHYSIOLOGY OF EXCESSIVE SCARRING

- At 1-2 weeks after wounding, re-epithelialisation is completed, but the stratum corneum is immature and allows abnormally high levels of TEWL. Dehydration of the stratum corneum occurs, perhaps via an osmotic gradient.[12]
- Keratinocytes are stimulated to produce cytokines, which in epidermal-dermal signalling activate dermal fibroblasts to synthesize and release collagen. Excessive collagen production leads to abnormal raised scarring.[12]

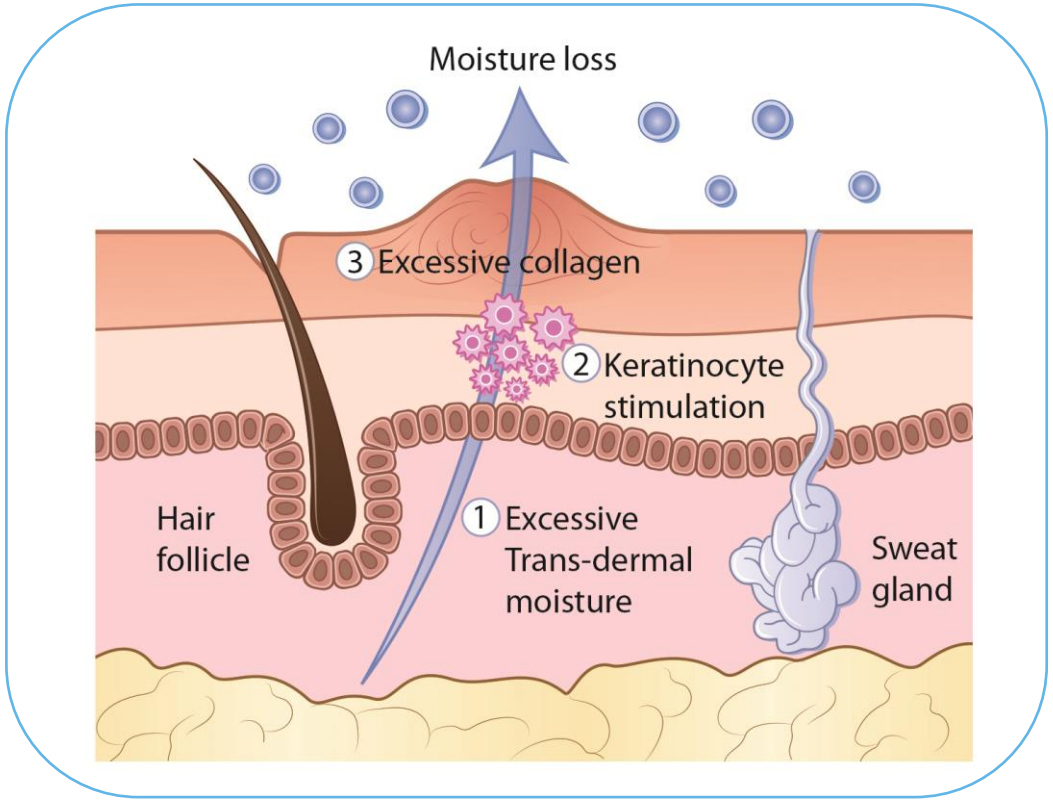

Adapted from http://biodermis.com.au/how-does-silicone-improve-scars

HYPERTROPHIC SCARS

- Appearance is due to excessive Type I and III collagen produced by fibroblasts that accumulate in a direction parallel to the epidermal surface[13]
- May eventually mature to a normal scar as fibroblasts are transformed into myofibroblasts leading to scar retraction[13]



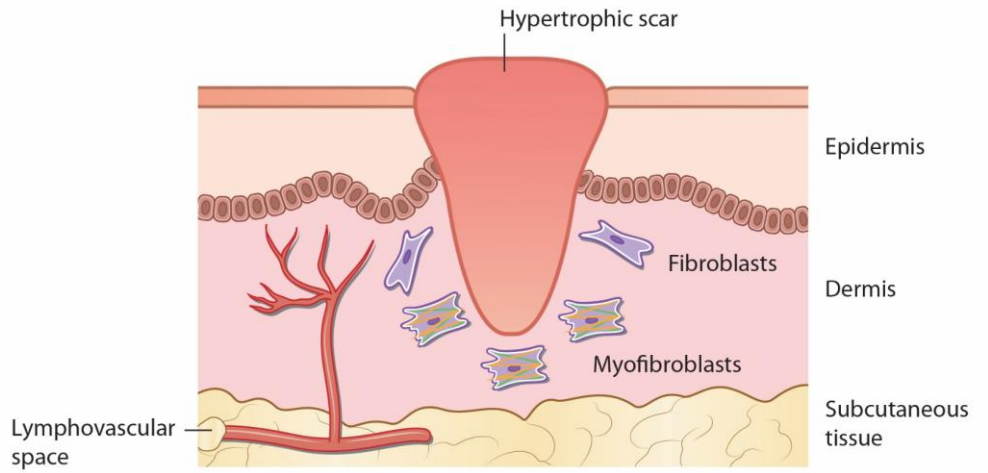

Adapted from Su, 2010

KELOIDS

- Appearance caused by the presence of disorganised Type I and III collagens with thick irregular branches[13]
- Do not mature (regress) to a normal scar as fibroblasts will not transform to myofibroblasts[13]
- High recurrence rates following surgical excision[14]
- May be linked to genetic susceptibility[6]



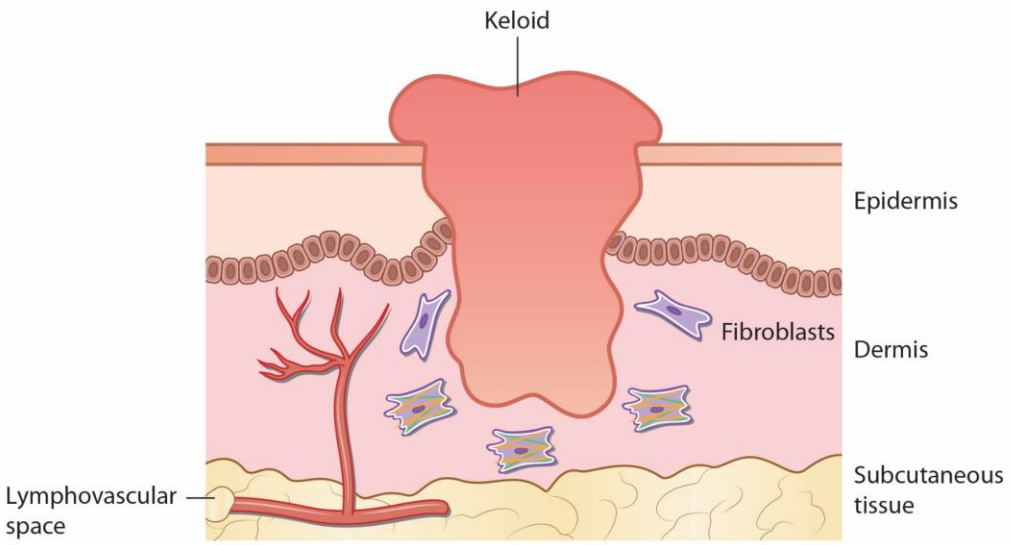

Adapted from Su, 2010

COMPARING HYPERTROPHIC SCARS AND KELOIDS

	Hypertrophic scars[14]	Keloids[14]
Appearance	Red or pink, raised and firm	Dark red or pigmented; raised, firm and irregular in shape
Extent of scar	Remain confined to the borders of the original wound	Grow beyond the borders of the original wound
Symptoms	May be itchy but rarely painful	Itchy and extremely painful, particularly during the growth phase
Predominant anatomical sites	No predominant sites but commonly occur on extensor surfaces of joints or in skin creases	Earlobes, chest, shoulders, upper back, back of the neck, cheeks, knees
Cause	Burns, trauma and surgery only	Spontaneous (genetic), burns, trauma and surgery
Contractures	Associated	Not associated
Change over time	May improve (regress or stabilise)	Continue to grow; no regression
Timeline	Generally appear after 1 month, grow for 6 months, then regress (often within a year)	Appear at 3 months or later than the initial scar, then gradually proliferate indefinitely
Association with skin pigmentation	No association	More common in darker skin types

EPIDEMIOLOGY OF EXCESSIVE SCARRING

Any excessive scarring	Hypertrophic scars	Keloids
• Occurs in 77% of burns patients[15]	• Occur in 67-91% of adult burns patients[14-16,18] • Occur in 16-17% of paediatric burns[19,20] • Occur following 40-75% of surgical procedures[16,17]	• Occur in 10-15% of all wounds[21] • 6-16% in black people[16]

THE PERSONAL BURDEN OF EXCESSIVE SCARRING[22]

Physical comfort and functioning
- Pain, itching, inflammation
- Altered texture and sensation
- Impaired physical function (contractures)

Acceptability to self and others
- Stigmatisation
- Satisfaction with appearance

Social functioning
- Personal relationships
- Sociability
- Work-life
- Ability to communicate
- Leisure activities

Emotional wellbeing
- Low self-confidence
- Anxiety
- Low mood
- Anger

Adapted from Brown, 2008

IMPACT OF SCARRING ON QUALITY OF LIFE[23]

- In a study of 130 patients in an outpatient clinic, the impact of different scar types on quality of life (QOL) was investigated
- The Dermatology Life Quality Index (DLQI) was used to assess patient impact
- Patients with keloids, atrophic and self-harm scars showed a pronounced effect on QOL, while hypertrophic scarring showed minor impact

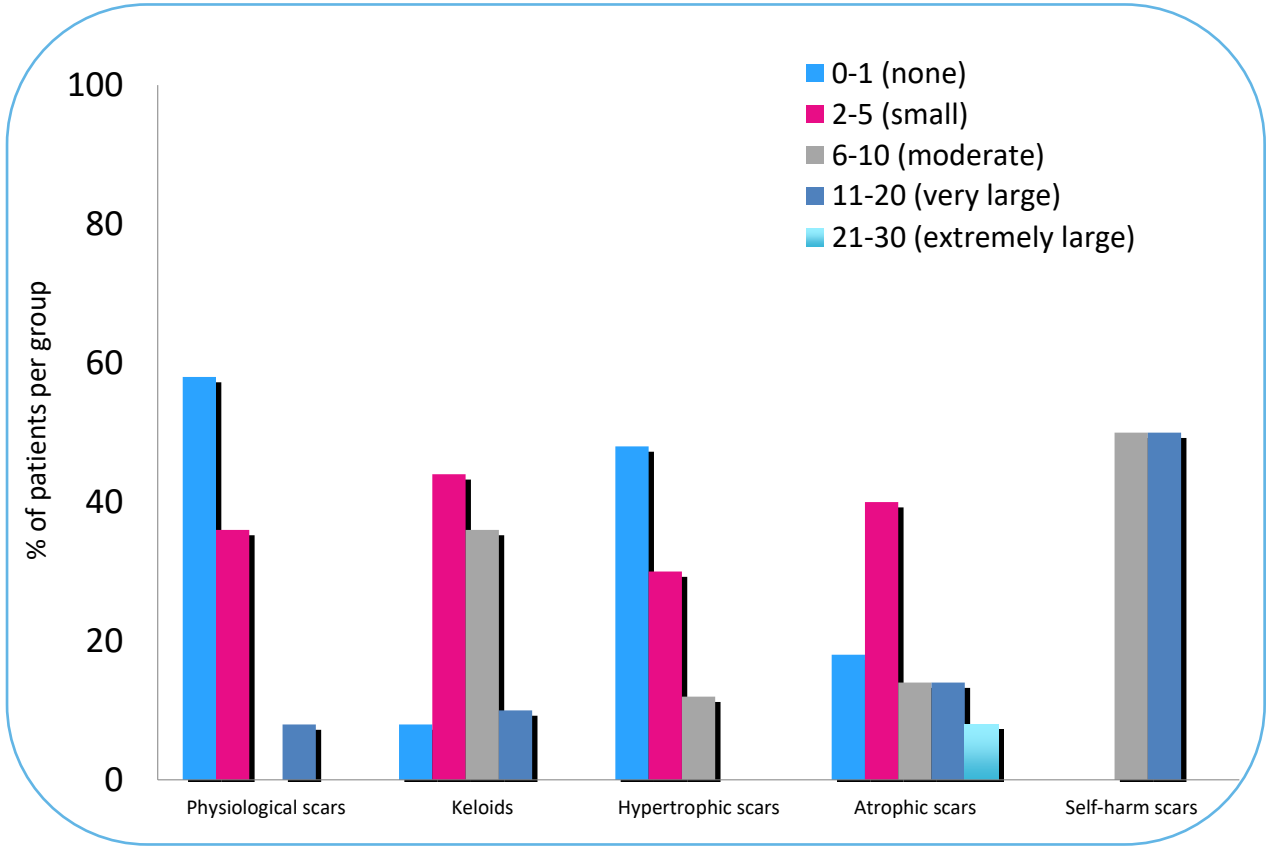

Adapted from Reinholz, 2015

Provided by:

KELO-COTE®
SCAR PREVENTION
& TREATMENT

Summary

SUMMARY

- The skin is composed of three layers – the epidermis, dermis and subcutis
- During normal wound healing there are four phases – haemostasis, inflammation, proliferation and remodelling/scar maturation
- Pathological scars include atrophic scars, hypertrophic scars and keloids
- Excessive scarring (hypertrophic scars and keloids) occur when there is excessive collagen production during the healing process
    - Keloid scars do not go through the remodelling phase, the fibroblasts will not transform to myofibroblasts
- These scars may be painful and unsightly, with a negative impact on the person's quality of life and self-esteem

Please note: KELO-COTE is not indicated to treat atrophic scars

Provided by:

KELO-COTE®
SCAR PREVENTION
& TREATMENT

Quiz Questions

QUESTION 1

What proportion of the epidermis is made up of keratinocytes?

A. At least 20%
B. At least 40%
C. At least 60%
D. At least 80%

QUESTION 2

True or false: keloids may invade the tissue surrounding the original site of the wound.

A. True

B. False

QUESTION 3

Which of the following is not a layer of the epidermis?

A. Stratum basale
B. Stratum corneum
C. Stratum granularis
D. Stratum granulosum

QUESTION 4

The appearance of hypertrophic scars is caused by the presence of excessive amounts of which type of collagen (please select two options):

A. Type I collagen
B. Type II collagen
C. Type III collagen
D. Type IV collagen

QUESTION 5

During which phase of healing is the extracellular matrix formed?

A. Haemostasis
B. Inflammation
C. Proliferation
D. Remodelling

QUESTION 6

True or false: scar tissue has only 50% of the strength of normal tissue.

A. True
B. False

QUESTION 7

The skin is involved in the production of which vitamin?

A. D
B. A
C. C
D. K

QUESTION 8

Where on the body is the epidermis thinnest?

A. Lips
B. Eyelids
C. Fingertips
D. Palms of the hands

QUESTION 9

True or false: obesity can affect wound healing.

A. True

B. False

QUESTION 10

How many children suffering burns develop hypertrophic scars?

A. 16-17%

B. 36-37%

C. 56-57%

D. 76-77%

Provided by:

KELO-COTE®
SCAR PREVENTION
& TREATMENT

Quiz Answers

QUESTION 1

What proportion of the epidermis is made up of keratinocytes?

A. At least 20%

B. At least 40%

C. At least 60%

D. At least 80%

QUESTION 2

True or false: keloids may invade the tissue surrounding the original site of the wound.

A. True

B. False

QUESTION 3

Which of the following is not a layer of the epidermis?

A. Stratum basale

B. Stratum corneum

C. Stratum granularis

D. Stratum granulosum

QUESTION 4

The appearance of hypertrophic scars is caused by the presence of excessive amounts of which type of collagen (please select two options):

A. **Type I collagen**

B. Type II collagen

C. **Type III collagen**

D. Type IV collagen

QUESTION 5

During which phase of healing is the extracellular matrix formed?

A. Haemostasis
B. Inflammation
C. Proliferation
D. Remodelling

QUESTION 6

True or false: scar tissue has only 50% of the strength of normal tissue.

A. True

B. False: it has ~80% of the strength of normal tissue.

QUESTION 7

The skin is involved in the production of which vitamin?

A. D

B. A

C. C

D. K

QUESTION 8

Where on the body is the epidermis thinnest?

A. Lips

B. Eyelids

C. Fingertips

D. Palms of the hands

QUESTION 9

True or false: obesity can affect wound healing.

A. **True**

B. False

QUESTION 10

How many children suffering burns develop hypertrophic scars?

A. **16-17%**
B. 36-37%
C. 56-57%
D. 76-77%

REFERENCES

1. Kolarsick P. A. J., et al., J Dermatol Nurs. Assoc. 2011; 3:p203-213.
2. Chapter 2. Hunter J, et al. Clinical dermatology. 3rd Ed. Oxford: Blackwell Publishing; 2002.
3. DermNet NZ. Structure of the epidermis CME. Available at: https://www.dermnetnz.org/cme/principles/structure-of-the-epidermis/ [Accessed Feb 2021].
4. DermNet NZ. Structure of the dermis and subcutis CME. Available at: https://www.dermnetnz.org/cme/principles/structure-of-the-dermis-and-subcutis/ [Accessed Feb 2021].
5. Thiruvoth F. M., et al., Plast. Aesth. Res. 2015; 2:p250-256.
6. Bayat A., et al., BMJ 2003; 326:p88-92.
7. Enoch S., Leaper D. J., Surgery 2008; 26:p31-37.
8. Guo S., DiPietro L. A., J. Dent. Res. 2010; 89: p219-229.
9. Kerwin L. Y., et al., Int. J. Dermatol. 2014; 53:p922-936.
10. Al-Shaqsi S., Al-Bulushi T., Sultan Qaboos University Med J 2016;16:e3–e8.
11. Patel L., et al., JRSM Open 2014; 5(9):p1-13.
12. Mustoe T. A. Aesth. Plast. Surg. 2008; 32:p82-92.
13. Su W., et al., Mediators Inflamm. 2010; Article ID 413238.
14. Arno A. I., et al., Burns 2014; 40:p1255-1266.
15. Gangemi E. N., et al., Arch Facial Plast. Surg. 2008; 10:p93-102.
16. Gauglitz G. G., et al., Mol. Med. 2011; 17:p113-125.
17. Li-Tsang C. W. P., et al., Burns 2005; 31:p610-616.
18. Bombaro K. M., et al., Burns 2003; 29:p299-302.
19. Chipp E., et al., Burns Trauma 2017; 5:p3.
20. Lonie S., et al., Burns 2017; 43:p509-513.
21. Chua S.H., et al. Trials 2019; 20:363. Available at: https://doi.org/10.1186/s13063-019-3465-6
22. Brown B.C., et al., J. Plast. Reconstr. Aesthet. Surg. 2008; 61:p1049-1058.
23. Reinholz M., et al., J. Eur. Acad. Dermatol. Venereol. 2015; 29:p2112-2119.