Provided by:

KELO-COTE®
SCAR PREVENTION
& TREATMENT

Training Manual

Module 2

The intended use of KELO-COTE is for the management of old (up to four years of age) and new hypertrophic and keloid scars resulting from general surgical procedures, trauma, wounds and burns.

Images purchased from Shutterstock unless otherwise stated

Job bag no. JB-000366
Date of preparation: Feb 2021

Provided by:

KELO-COTE®
SCAR PREVENTION
& TREATMENT

Management of Scarring

OBJECTIVES

At the end of this session, you should be able to:

- List the preventive measures for excessive scarring
- Discuss the current guidelines for the management of hypertrophic and keloid scars
- Summarise invasive and non-invasive methods of excessive scarring management
- Describe the mechanism of action for silicone in scar healing
- Explain the key rating scales for determining the severity of scarring

Provided by:

KELO·COTE®
SCAR PREVENTION
& TREATMENT

General Management of Wounds and Scarring

Please note that some of the following information may constitute off label use.

This information has been taken directly from published papers and guidelines and is not intended to be promotional

GUIDELINES FOR EXCESSIVE SCAR PREVENTION[1*]

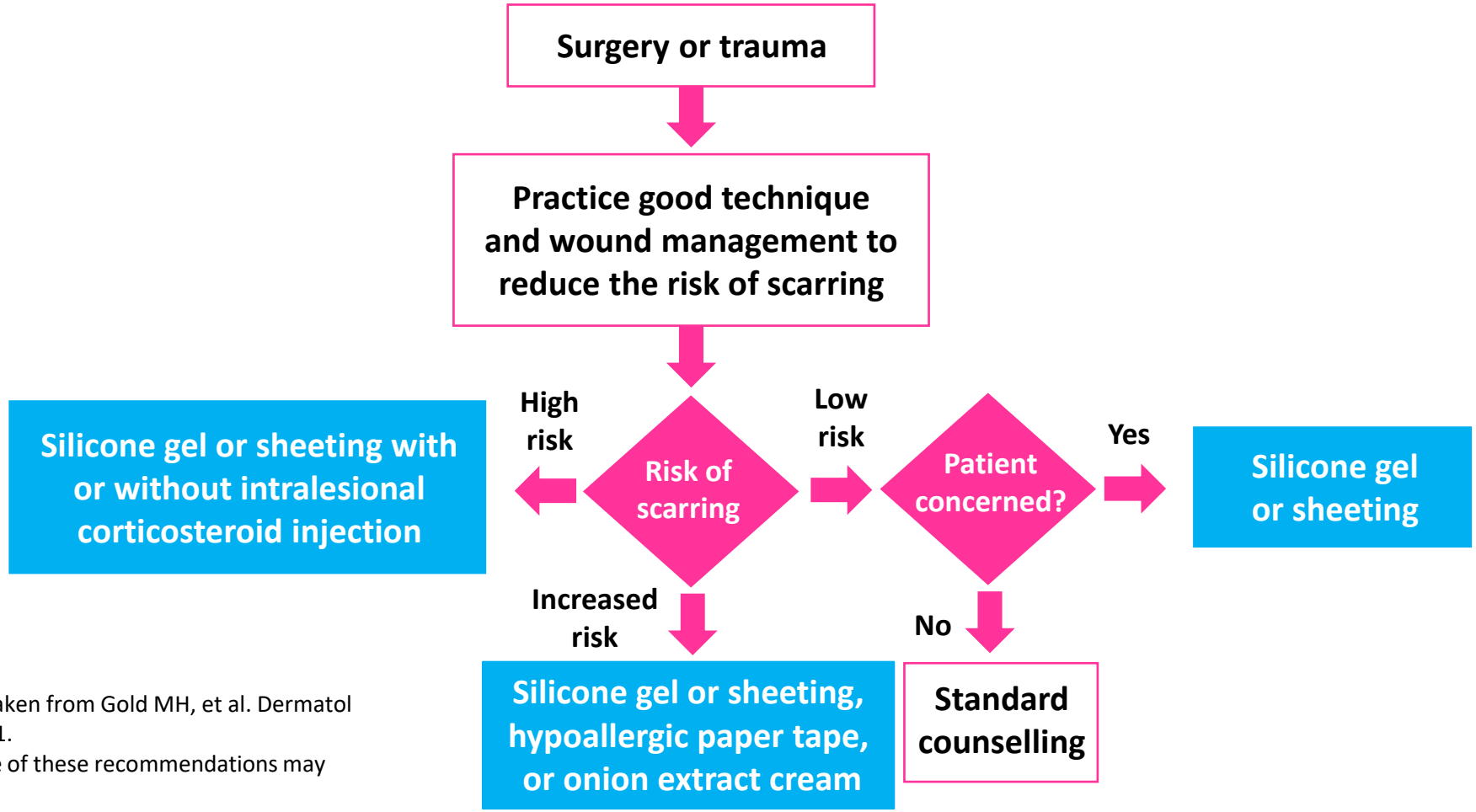

*Recommendations taken from Gold MH, et al. Dermatol Surg 2014;40:825–831.
Please note that some of these recommendations may include off-label use.

PREVENTIVE MEASURES[2]

- There are number of factors that can enhance normal wound healing and scarring
- Interventions are often used in combination

Surgical factors
- Rapid wound closure
- Debridement of dead tissue

Protective measures
- Prevention of inflammation and infection
- Dressings that provide a moist healing environment
- Sun protection

Physical measures
- Manual or mechanical massage
- Taping, splinting
- Stretching
- Physiotherapy
- Moisturisation

The number of preventive measures employed depends on the individual patient's risk of scar formation, together with their concerns about scar formation

SURGICAL FACTORS: MINIMISING TENSION

- For patients undergoing elective surgery placement of the incision line can help to reduce scarring
  - If possible, it should be parallel to relaxed skin tension lines[3,4]
- Heightened tension pulls the edges of a wound apart, leading to collagen deposition and hypertrophic scarring[4]
- The area of the body may dictate the level of tension[4]
- Those that have a greater tension on the skin and an increased risk of scar formation include:[2-4]
  - The deltoid (back of the shoulder), sternal (breastbone) and lower abdominal regions

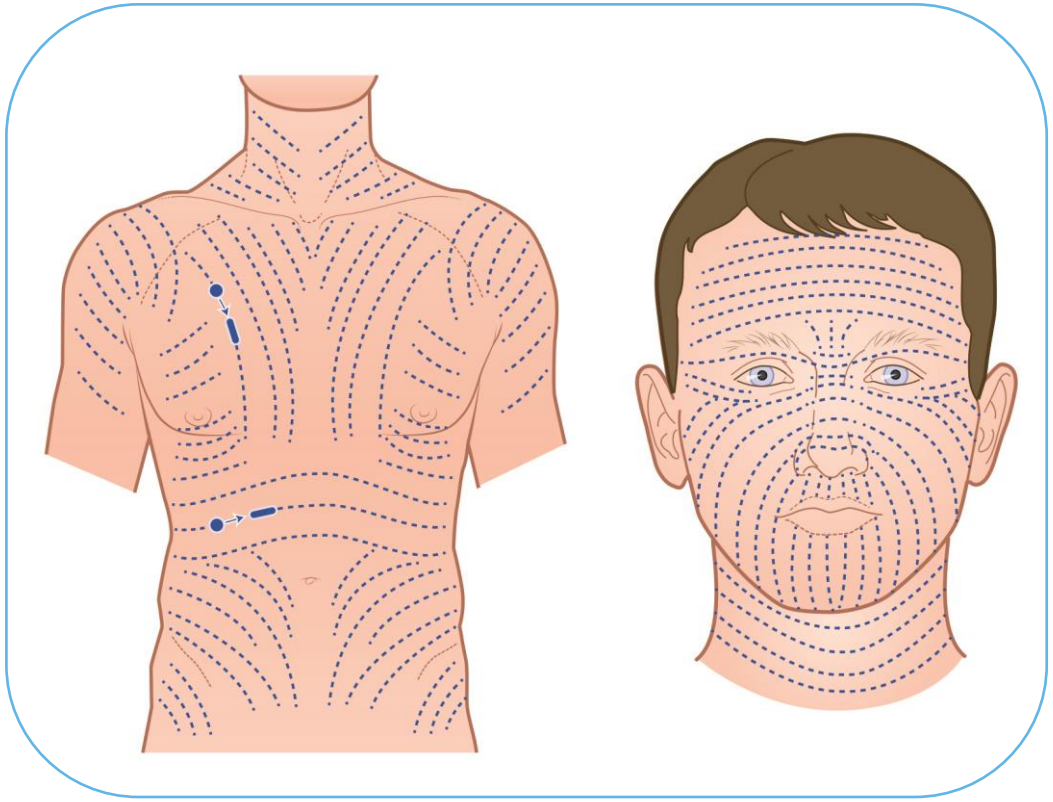

Adapted from Son, 2014

SURGICAL FACTORS: WOUND CLOSURE

- Rapid skin closure is essential for normal wound healing[2]
- Dead skin and the need for debridement (removal) typically occurs only in chronic, unhealed wounds, e.g. diabetic ulcers or when treatment of an acute wound is delayed[5,6]
- Non-absorbable sutures such as those made of nylon should be removed as soon as the edges of wound can hold themselves together[4]

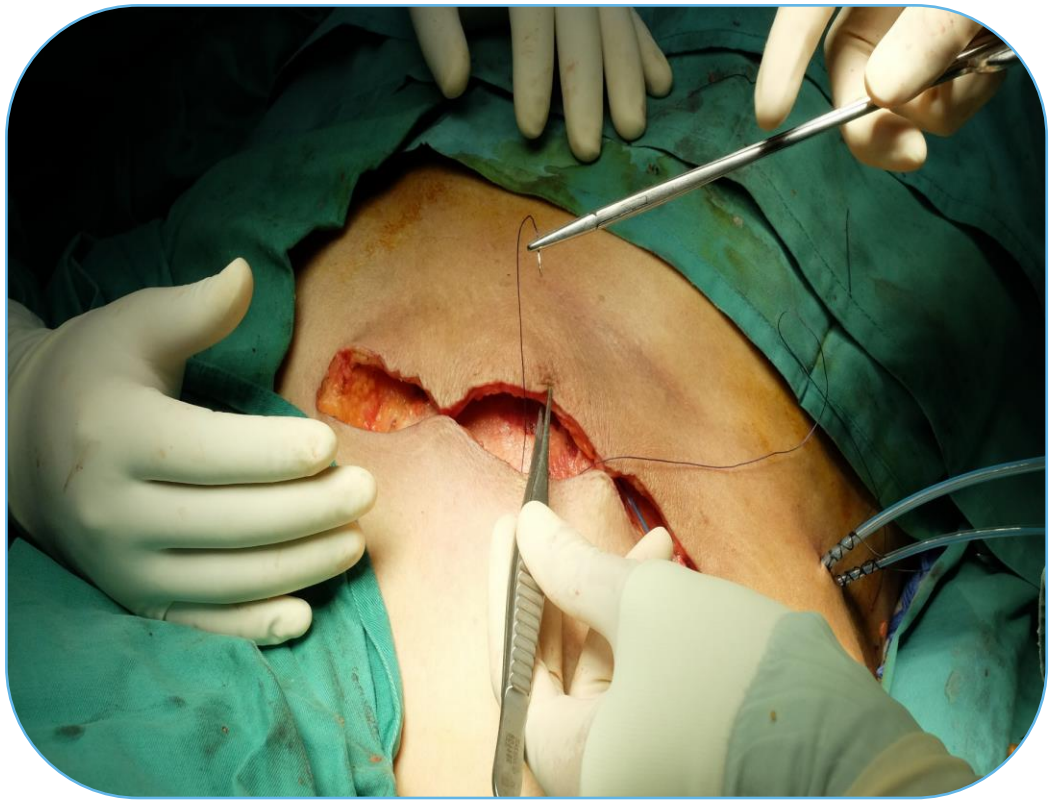

CLEANING THE WOUND AND PREVENTING INFECTION

- Removal of dead skin by debridement can reduce the risk of infection[7]
- Wounds should only be washed with clean water or saline rather than alcohol or antiseptics[4]
- Occlusive dressings keep out microbes[8]



RETAINING MOISTURE

- Keeping the wound environment moist is important for healing[3]
  - It may reduce the size of scars
  - It is particularly useful for itchy scars
- There are two main ways of retaining moisture:[9]
  - The application of specific creams
  - Moisture retaining dressings such as silicone sheeting or gel



MASSAGE

- Scar massage is often recommended after burn injury and post-surgical scars[9]
- The mechanism of action for scar massage is unclear[9]
- However, there is some evidence that it may prevent and improve hypertrophic scars[9,10]
  - It can reduce scar pain, itching, thickness, discolouration and redness
  - It may also decrease transepidermal water loss

Effleurage: repeated circular stroking movements with the palm of the hand[10,11]

Petrissage: using kneading movements [10,11]

Friction massage: a deep pressure massage typically done using the ball of the thumb with small circular movements[10,11]

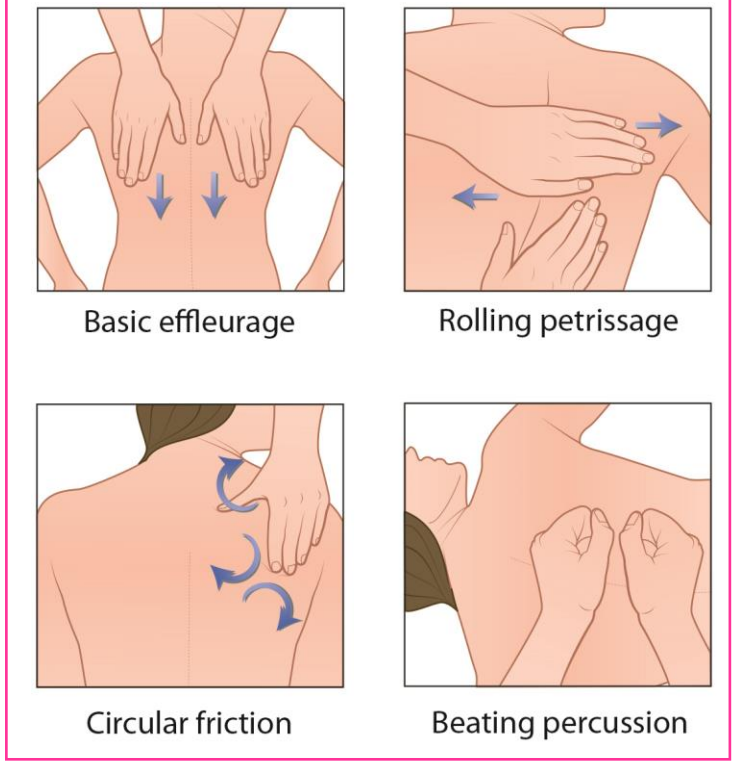

Adapted from https://nurseslabs.com/providing-back-care-massage

TAPING

- The application of specialised skin tape acts to reduce wound tension and support the scar tissue while it becomes stronger[4]
- The tape is made from a non-stretchy, inflexible microporous paper[12]
- Taping typically begins after sutures are removed and should continue for at least 3 months as this is the time period when hypertrophic scars may develop[4,12]



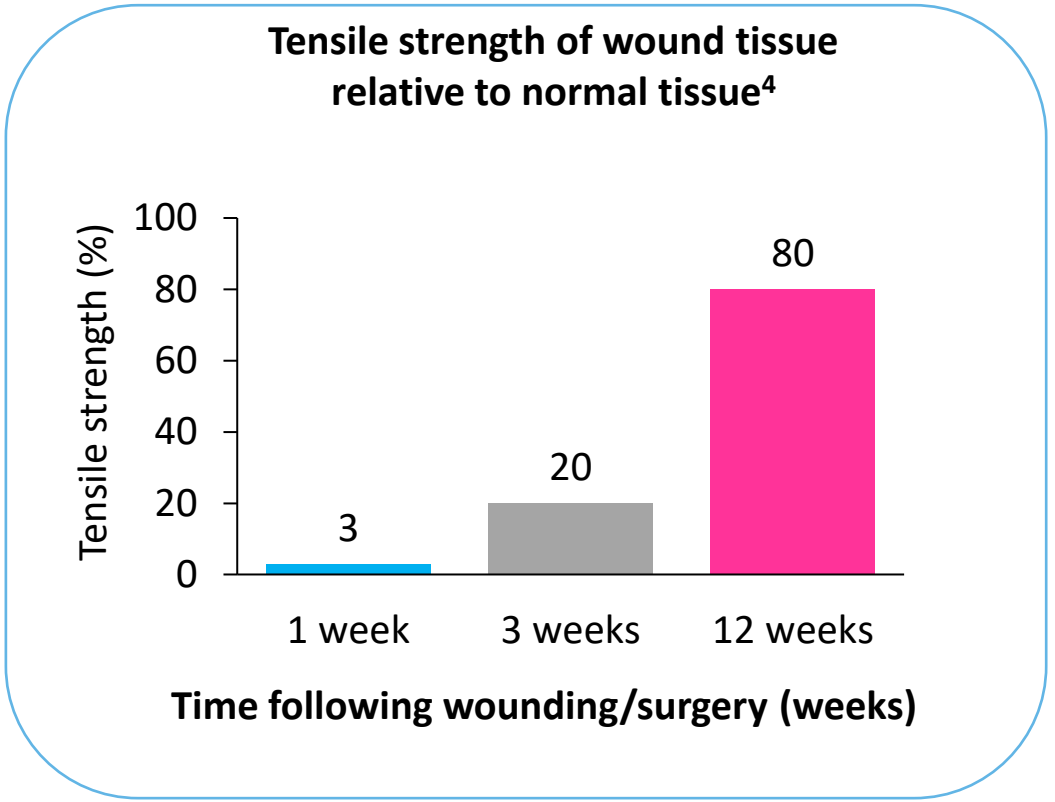

Adapted from Son, 2014

PRESSURE DRESSINGS AND GARMENTS[13]

- For some wounds it is recommended that pressure dressings be worn for 23 hours/day for ≥6 months to prevent hypertrophic scars and keloids
- It may be difficult to find a garment that fits the wounded area properly
- Patients often find wearing the dressings or garments uncomfortable and do not always adhere to guidance



Image purchased from Science Photo Library

GUIDELINES FOR HYPERTROPHIC SCAR TREATMENT[1*]

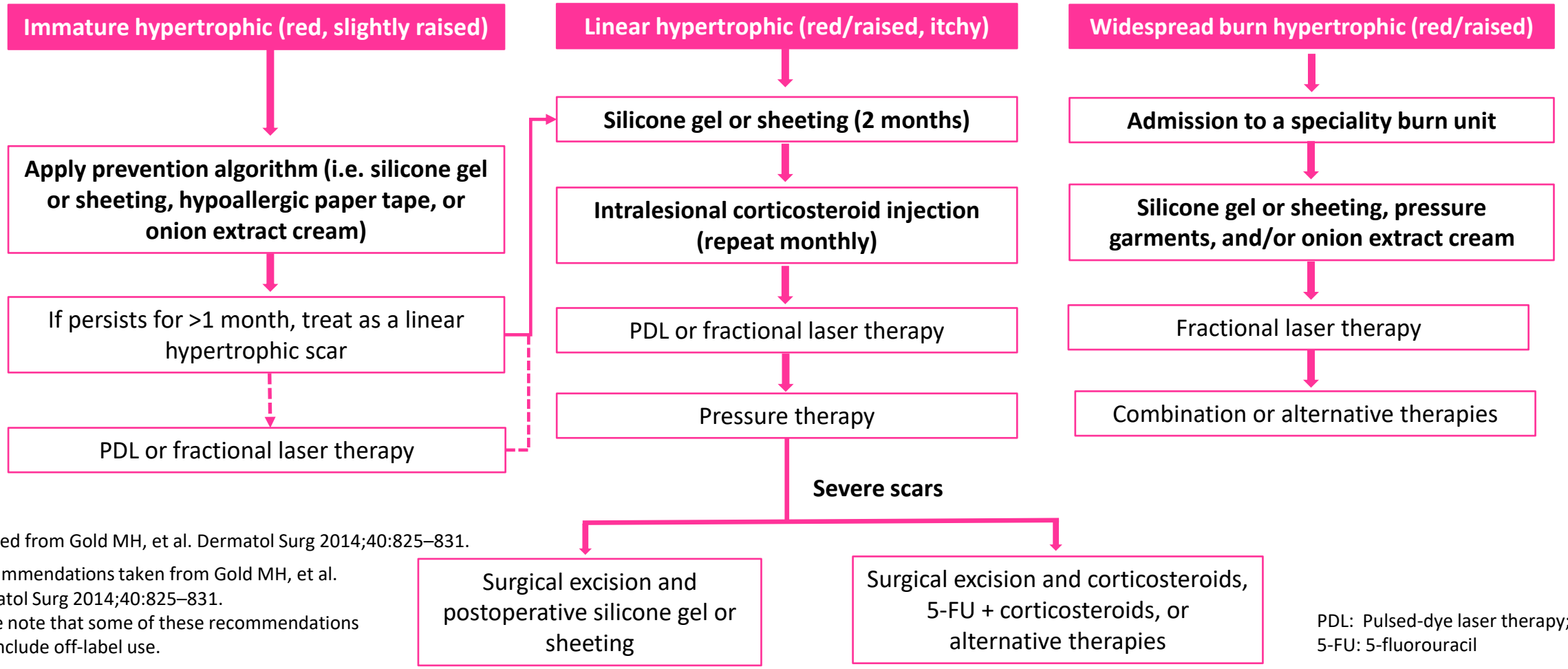

Adapted from Gold MH, et al. Dermatol Surg 2014;40:825–831.

*Recommendations taken from Gold MH, et al. Dermatol Surg 2014;40:825–831.
Please note that some of these recommendations may include off-label use.

PDL: Pulsed-dye laser therapy;
5-FU: 5-fluorouracil

GUIDELINES FOR HYPERTROPHIC SCAR TREATMENT[1*]

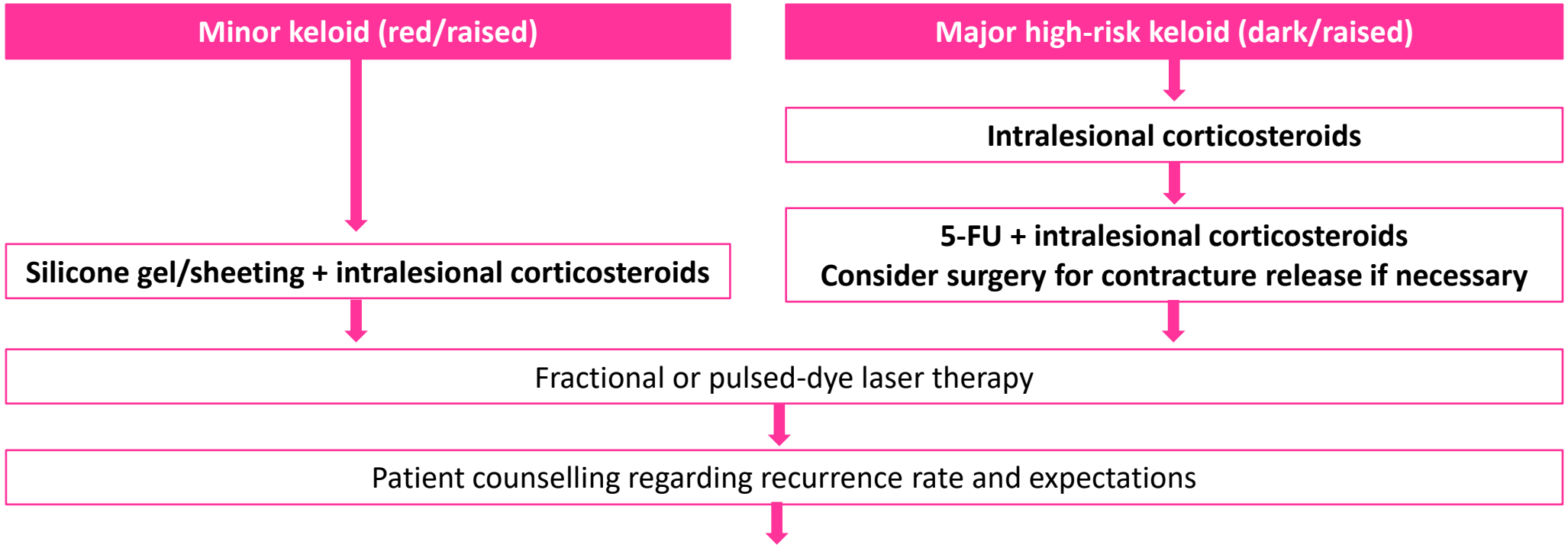

Adapted from Gold MH, et al. Dermatol Surg 2014;40:825–831.
*Recommendations taken from Gold MH, et al. Dermatol Surg 2014;40:825–831. Please note that some of these recommendations may include off-label use.

5-FU: 5-fluorouracil

ONION EXTRACT PRODUCTS

- It has been proposed onion extracts inhibit fibroblast proliferation and collagen production[14]
- The clinical efficacy of onion extract in scar prevention and treatment remains largely unproven, although there is some evidence supporting efficacy[9]



LASER THERAPY

- Some types of lasers are used to remove major scars[2,9]
  - Fractional CO_2 lasers work by ablating tissue gradually with each pass of the laser
  - In addition, their thermal energy can remodel collagen to make the fibres thinner and more organised
  - However, lasers are most often used to improve scar texture, spider veins or hyperpigmentation, or to prevent scar recurrence after a surgical revision[1]
- Non-ablative fractional lasers (e.g. the non-ablative 1565 mm fractional laser) thermally denature epidermal and dermal collagen but retain the skin's barrier function as they spare the stratum corneum[15,16]
- Lasers are always be used in combination with occlusion or compression[2]
- Laser therapy is often immediately followed by intralesional or laser-assisted delivery of corticosteroids[2]



INTRALESIONAL CORTICOSTEROIDS

- Some corticosteroids, e.g. triamcinolone acetonide, are commonly used in scar management[2,13]
- However, injections may be very painful and decrease compliance[3]
- Common adverse effects of intralesional corticosteroids include skin atrophy, “spider veins” and loss of pigmentation[13,17]

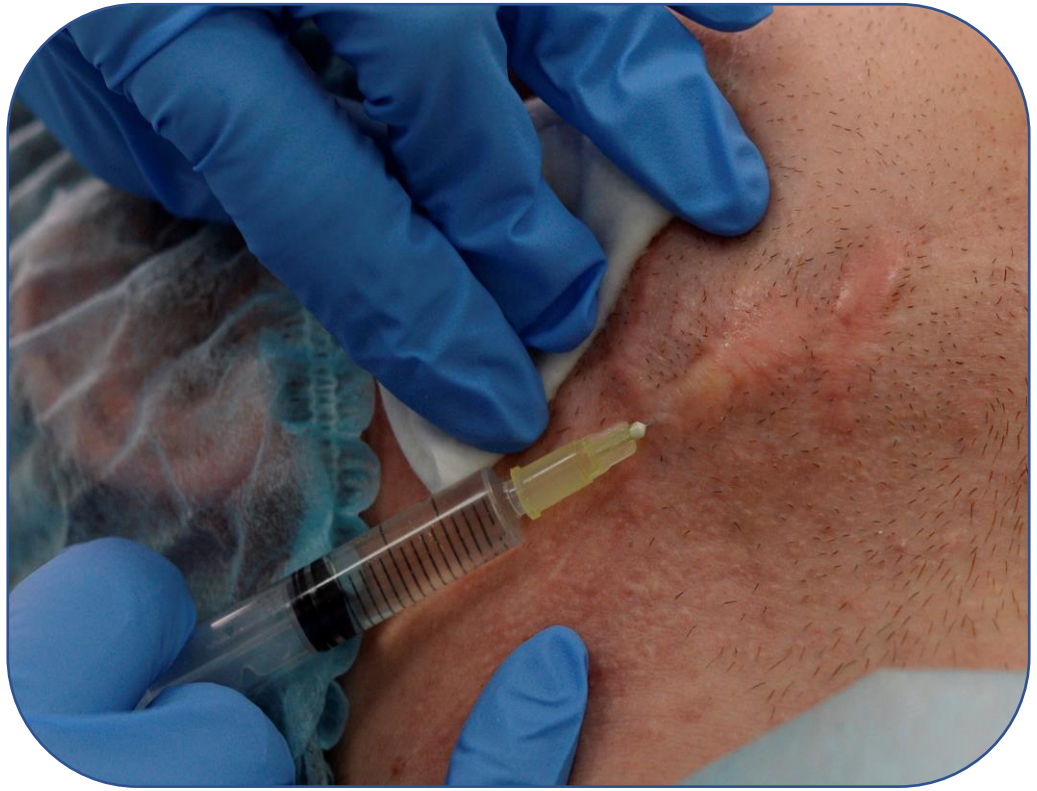

Image purchased from Science Photo Library

SURGICAL CONTRACTURE RELEASE

- Release of contractures may be necessary at an early stage if a hypertrophic scar is impeding function or rehabilitation[18]
- This may involve “z-plasty”, use of skin substitutes or skin grafts[18]

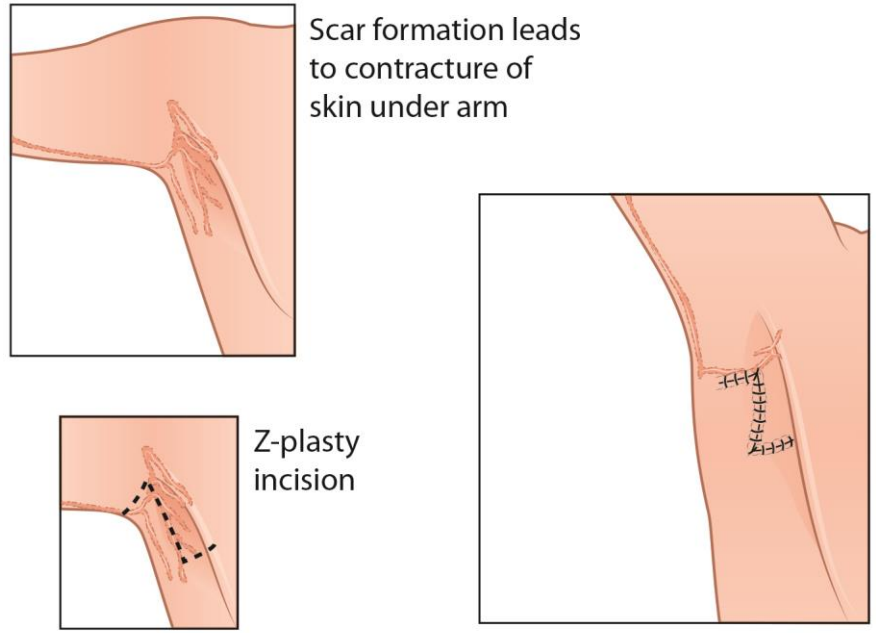

SURGICAL EXCISION OF KELOIDS

- Removal of the entire keloid mass[19]
- Intramarginal:[19]
  - The keloid is dissected from the covering skin
  - As the keloid stretches the skin, following removal there is sufficient excess skin so that the wound can be repaired without tension
- Extramarginal:[19]
  - Removes the keloid and covering skin to leave a linear scar
  - Maintaining appropriate tension with sutures can be difficult
  - Skin grafts or local flaps are often needed to achieve wound closure
- Combination with intralesional corticosteroids, pressure or radiotherapy is required to reduce recurrence rates[19,20]

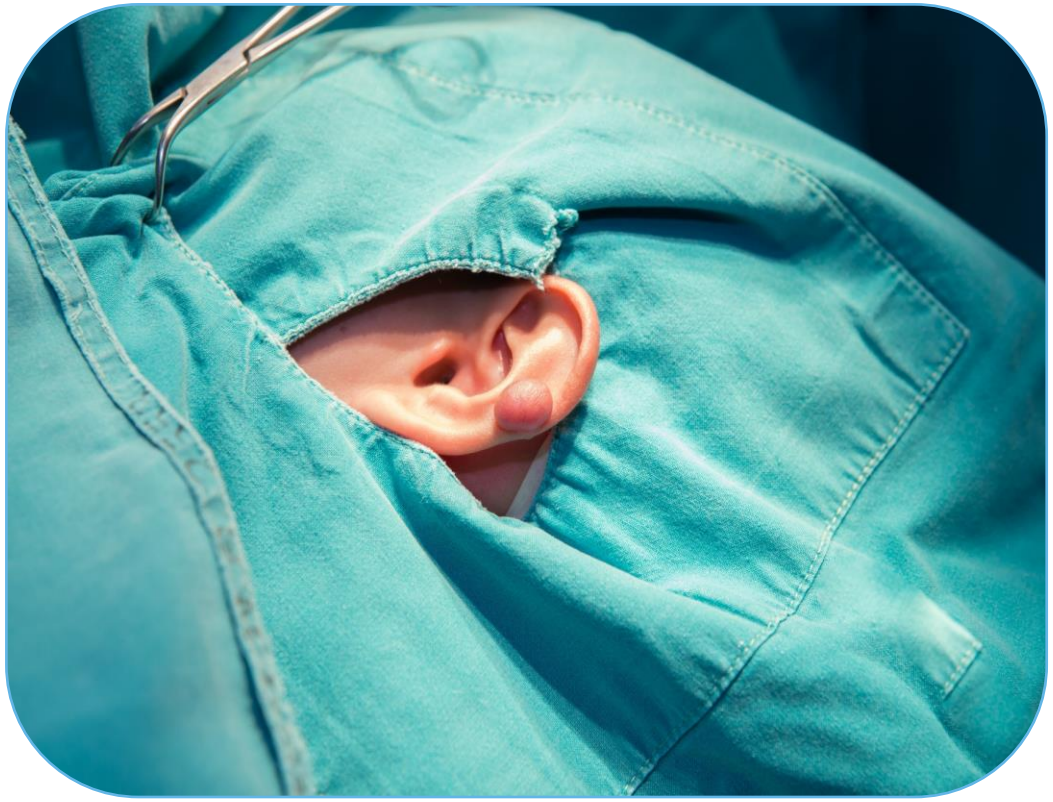

INTRALESIONAL CRYOTHERAPY FOR KELOIDS

- A specially designed “cryoneedle” is attached to a canister of liquid nitrogen[21,22]
- The cryoneedle is inserted lengthways into the keloid in order to freeze deep scar tissue[22]
- Cryotherapy can achieve improvements in scar volume, pain, itching, hardness and colour[21,22]
- However, this technique is limited to the treatment of very small scars[22]
- A period of several weeks between sessions is needed to allow for post-operative healing[22]
- Acute side effects include local oedema and increased fragility of the skin[22]
- Permanent hypopigmentation is a common side-effect of cryotherapy[22] however, this has been described as minimal[21]

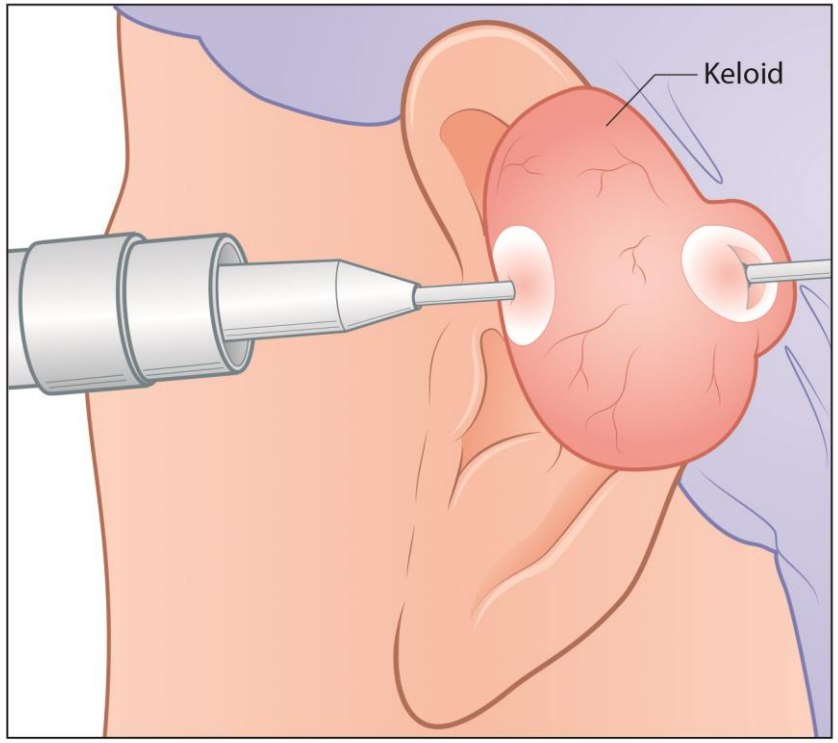

Adapted from http://idnps.com/clinical/scar-treatment/3-drugs-and-topical-agents-for-hypertrophic-scar-and-keloid-treatment-i/

LOCALISED RADIOTHERAPY OF KELOIDS

- Used following surgical excision of keloids to prevent recurrence[20,23]

Brachytherapy with iridium or cobalt[20,23]

- Radiation source is placed within or on the keloid
- High-dose brachytherapy is delivered via a catheter inserted into the keloid
- Superficial treatment without damage to underlying structures
- Can treat a broad area of skin without radiation dose drop-off

Electron beam radiotherapy[20,23]

- External radiation source
- Delivers photons (X-rays) levels to penetrate keloids to a depth of 2-6 cm
- The dose of radiation depends on the site of the keloid – high-tension areas need greater doses

Acute side effects (7-10 days)[23]

- Redness, swelling, skin shedding, ulceration, necrosis

Late side effects (weeks to months after radiation)

- Hypopigmentation or hyperpigmentation, skin atrophy, hair loss, spider veins

Provided by:

KELO-COTE®
SCAR PREVENTION
& TREATMENT

Introduction to Silicone in Scar Management

GUIDELINES

- Silicone therapy is recommended in the **Updated International Clinical Recommendations on Scar Management – Parts 1 and 2** (2014) as:[1,24]
  - **First-line** prevention of hypertrophic scars and keloids
  - **First-line** management of early and continuing hypertrophy of linear scars
  - **First-line** management of early keloids and following surgical excision of keloids

HOW DOES SILICONE WORK IN SCAR MANAGEMENT?

- Numerous hypotheses have been put forward regarding the mechanism of action of silicone in scar management
- However, it is widely recognised that silicone provides an optimal healing environment by:[25]
  - Occlusion of the closed wound, leading to hydration of the stratum corneum (the outermost layer of the epidermis) by reducing transepidermal water loss

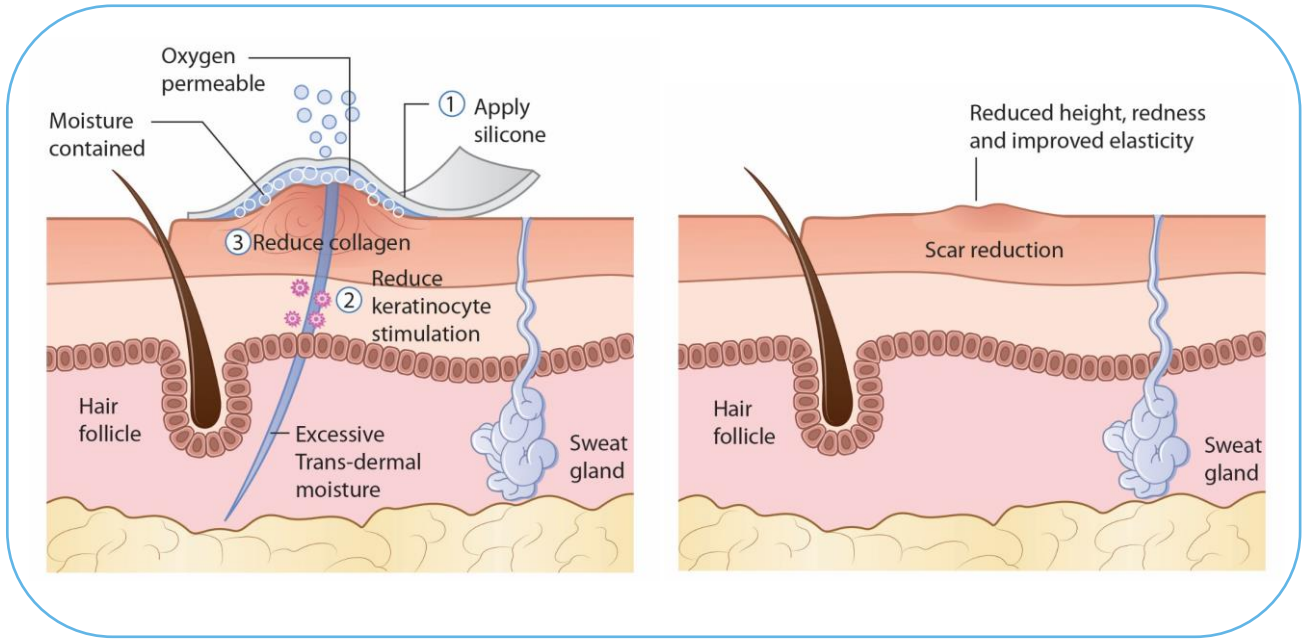

Adapted from http://biodermis.com.au/how-does-silicone-improve-scars

WHAT IS “OCCLUSION”?

- Occlusion is the sealing off of the wound and its immediate surrounding area to protect from microbes and trauma[8,26]
- Additionally, occlusive dressings keep the wound moist[8,26]
- This can be achieved not only with silicone but other types of dressing that are non-absorbable[26]
- However, these dressings often need to be fixed into place with medical tape[26]



REDUCTION OF TRANSEPIDERMAL WATER LOSS[2,25]

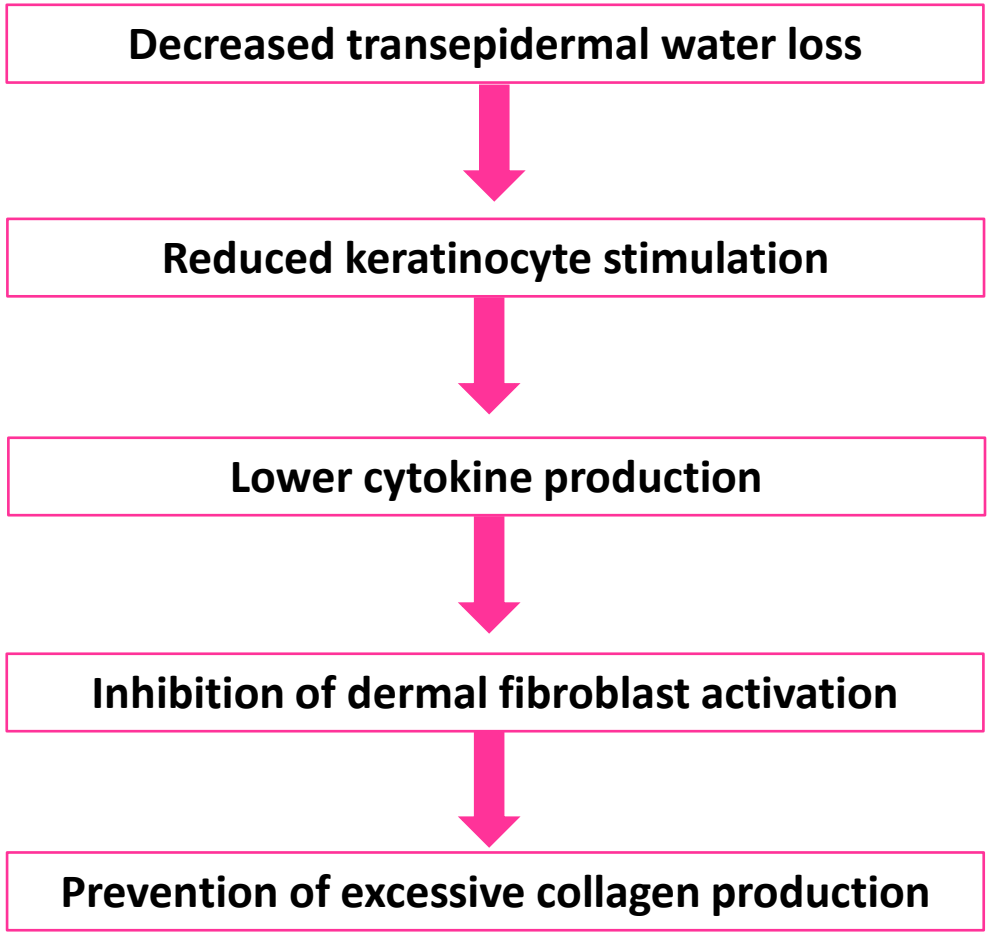

Provided by:

KELO-COTE®
SCAR PREVENTION
& TREATMENT

Measuring and Grading Scars

TOOLS USED TO MEASURE SCARS AND HEALING

- A number of tools are used to measure scars and their response to treatment
- However, these are generally only used in clinical trials rather than routine clinical practice
  - Reasons for this include perceived irrelevance, non-specificity, lack of familiarity, poor inter-rater reliability and time consumption[27]
- The mostly widely-used is the Vancouver Scar Scale (VSS)[27]
- The Patient and Observer Scar Assessment Scale is also commonly used (POSAS)[28]

THE VANCOUVER SCAR SCALE[27]

- A clinician-rated scale where a higher score means a more severe scar
- However, there is no consensus regarding a score that determines a hypertrophic scar

Pigmentation	**Vascularity**	**Pliability**	**Height**
0: Normal	0: Normal	0: Normal	0: Normal (flat)
1: Hypopigmentation	1: Pink	1: Supple	1: 0–2 mm
2: Hyperpigmentation	2: Red	2: Yielding	2: 2–5 mm
	3: Purple	3: Firm	3: >5 mm
		4: Banding	
		5: Contracture	

PATIENT AND OBSERVER SCAR ASSESSMENT SCALE[28]

- A patient- and clinician-rated tool
- Scars are scored using visual analogue scales
- A higher score means a more severe scar
- The patient-rated section also takes into account pain and itching

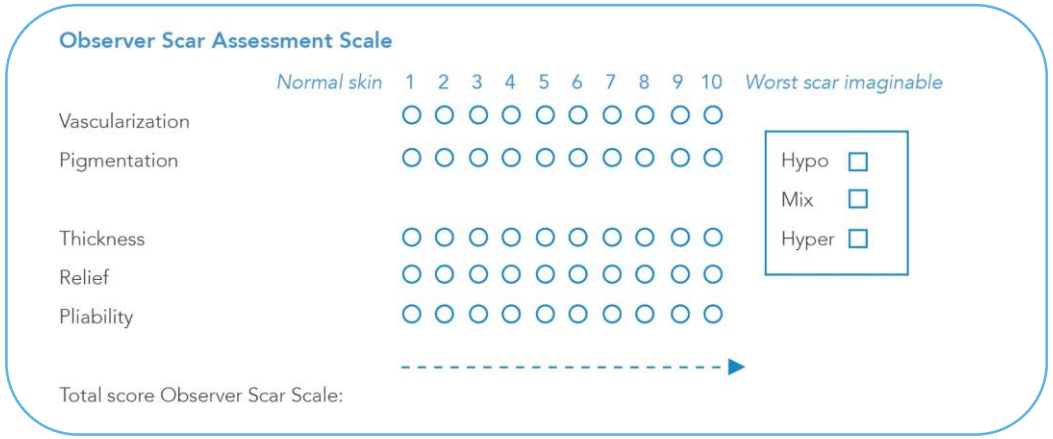



Adapted from Draaijers, 2004

Provided by:

KELO-COTE®
SCAR PREVENTION
& TREATMENT

Summary

SUMMARY

- There are a number of measures that can be employed to prevent the development of excessive scarring, including reduced tension at the wound site after closure and physical therapies such as tapping, pressure and massage
- In patients with hypertrophic scars, release of contractures by surgery can enhance rehabilitation and function
- The use of intralesional therapies such as corticosteroids, 5-fluorouracil, bleomycin and verapamil is commonly referred to in current guidelines
- To minimise recurrence rates, surgery is typically followed by radiotherapy or cryotherapy for keloids
- Guidelines recommend that silicone is a first-line option for prevention of hypertrophic scars and keloids, and management of early and growing hypertrophic scars and keloids
- The Vancouver Scar Scale and Patient and Observer Scar Assessment Scale enable measurement of scar severity by morphology and impact on the patient

Provided by:

KELO-COTE®
SCAR PREVENTION
& TREATMENT

Quiz Questions

QUESTION 1

Which of the following is not a guideline-recommended intralesional therapy for hypertrophic scarring or keloids?

A. 5-fluorouracil
B. Iridium
C. Bleomycin
D. Verapamil

QUESTION 2

True or false: extramarginal excision of keloids requires skin flaps or skin grafts to close the wound.

A. True

B. False

QUESTION 3

Which of the following is the approximate tensile strength of wound tissue relative to normal skin at 3 weeks after injury?

A. 10%

B. 20%

C. 30%

D. 40%

QUESTION 4

Electron beam radiotherapy can penetrate skin to a depth of up to:

A. 2 mm
B. 2 cm
C. 6 mm
D. 6 cm

QUESTION 5

Which 4 features of a scar's appearance are rated using the Vancouver Scar Scale?

A. Pigmentation, vascularity, pliability, height
B. Pigmentation, vascularity, pliability, diameter
C. Pigmentation, itchiness, pliability, height
D. Pigmentation, vascularity, scaliness, height

QUESTION 6

True or false: permanent hyperpigmentation is a side effect of intralesional cryotherapy.

A. True

B. False

QUESTION 7

The application of silicone to a wound or scar allows hydration of which layer of the skin?

A. Dermis
B. Stratum basale
C. Subcutis
D. Stratum corneum

QUESTION 8

What is the term for surgical removal of dead skin?

A. Resurfacing
B. Debridement
C. Petrissage
D. Revision

QUESTION 9

True or false: the development of spider veins is a side-effect of intralesional corticosteroid therapy.

A. True

B. False

QUESTION 10

Which of the following is not a type of massage usually used for the management of scarring?

A. Effleurage
B. Friction
C. Jambe
D. Petrissage

Provided by:

KELO-COTE®
SCAR PREVENTION
& TREATMENT

Quiz Answers

QUESTION 1

Which of the following is not a guideline-recommended intralesional therapy for hypertrophic scarring or keloids?

A. 5-fluorouracil

B. Iridium

C. Bleomycin

D. Verapamil

QUESTION 2

True or false: extramarginal excision of keloids requires skin flaps or skin grafts to close the wound.

A. True

B. False

QUESTION 3

Which of the following is the approximate tensile strength of wound tissue relative to normal skin at 3 weeks after injury?

A. 10%

B. 20%

C. 30%

D. 40%

QUESTION 4

Electron beam radiotherapy can penetrate skin to a depth of up to:

A. 2 mm
B. 2 cm
C. 6 mm
D. 6 cm

QUESTION 5

Which 4 features of a scar's appearance are rated using the Vancouver Scar Scale?

A. **Pigmentation, vascularity, pliability, height**
B. Pigmentation, vascularity, pliability, diameter
C. Pigmentation, itchiness, pliability, height
D. Pigmentation, vascularity, scaliness, height

QUESTION 6

True or false: permanent hyperpigmentation is a side effect of intralesional cryotherapy.

A. True

B. False. Permanent hypopigmentation is a side effect of intralesional cryotherapy.

QUESTION 7

The application of silicone to a wound or scar allows hydration of which layer of the skin?

A. Dermis

B. Stratum basale

C. Subcutis

D. Stratum corneum

QUESTION 8

What is the term for surgical removal of dead skin?

A. Resurfacing

B. Debridement

C. Petrissage

D. Revision

QUESTION 9

True or false: the development of spider veins is a side-effect of intralesional corticosteroid therapy.

A. True

B. False

QUESTION 10

Which of the following is not a type of massage usually used for the management of scarring?

A. Effleurage

B. Friction

C. Jambe

D. Petrissage

REFERENCES

1. Gold M.H., et al., Dermatol. Surg. 2014; 40:p825-831.
2. Meaume S., et al., Eur. J. Dermatol. 2014; 24:p435-443.
3. Monstrey S., et al., J. Plast. Reconstr. Aesth. Surg. 2014; 67:p1017-1025.
4. Son D., Harijan A., J. Korean Med. Sci. 2014; 29:p751-757.
5. World Health Organization. Wound management. 2009.
6. Guo S., DiPietro L. A., J. Dent. Res. 2010; 89:p219-229.
7. Atkin L., A guide to wound debridement. Independent Nurse 2016. http://www.independentnurse.co.uk/clinical-article/a-guide-to-wound-debridement/114500/ [Accessed Oct 2020].
8. Schultz G. S., et al., Wound Rep. Regen. 2003; 11:p1-28.
9. Khansa I,. et al., Plast. Reconstr. Surg. 2016; 138:p165S-1678.
10. Cho Y. S., et al., Burns 2014; 40:p1513-1520.
11. Nurseslabs. Providing back care and massage. https://nurseslabs.com/providing-back-care-massage/ [Accessed Oct 2020].
12. Atkinson J. M., et al., Plast. Reconstr. Surg. 2005; 116:p1648-1656.
13. Gauglitz G. G., et al. Mol. Med. 2011; 17:p113-125.
14. Poetschke J., Gauglitz G. G., J. Dtsch. Dermatol. Res. 2016; 14:p467-477.
15. Beasley K., et al., Curr. Derm. Rep. 2013; 2:p135-143.
16. Clementoni M. T., Lavagno R., J. Cosmet. Laser Ther. 2015; 17:p148-155.
17. Juckett G., et al., Am, Fam, Physician 2009; 80:p253-260.
18. Arno A. I., et al., Burns 2014; 40:p1255-1266.
19. Walliczek U., et al., JAMA Facial Plast. Surg. 2015; 17:p333-339.
20. Hoang D., et al., Aesth. Surg. J. 2017; 37:p212-225.
21. Trisliana Perdanasari A., et al., Arch Plast. Surg. 2014; 41:p620-629.
22. Atiyeh B. S., Aesth. Plast. Surg. 2007; 31:p468-492.
23. Cheraghi N., et al., J. Clin. Aesthet. Dermatol. 2017; 10:p12-15.
24. Gold M. H., et al., Dermatol. Surg. 2014;p817-824.
25. Mustoe T. A., Aesth. Plast. Surg. 2008; 32:p82-92.
26. Rheinecker S. B., J. Ath. Train 1995; 30:p143-145.
27. Thompson C. M., et al., Burns 2015; 41:p1442-1448.
28. Draaijers L. J., et al., Plast. Reconstr. Surg. 2004; 113:p1960-1965.